PLAINTIFF'S EXHIBIT

GP-1450

1974

AKRON, NY

GYPSUM-

ASBESTOS TESTING

SGP 0022077

MC CARGAR, Francis Employed: Georgia-Pacific

Francis McCargar 121-07 [illegible]

77 [illegible] 59 [illegible]

[illegible]

Alleges cough and shortness of breath and significant pipe and cigarette smoking for many years.

OCT 14 1974

[illegible]

Work on Ready Mix in the Jt Syst Dept for app. 3 or 4 yrs.

VENTILATION STUDY

FVC: 2000 cc
FEV1: 45%
FEV2: 65%
FEV3: 80%
FEF 25%-75%: 0.6 L/sec
M.V.V. 55 L/min

Marked evidence of both restrictive and and airway obstructive disease. Certainly compatible with any subjective complaint, although examinee indicates no disability.

SGP 0022078

[illegible]: 3843 #3843

Marked fibrosis of both roots and all lobes. Multiple small calcific densities noted in each root and in the right lower lobe. Fibrosis in the peripheral lung fields are characterized by the rounded and irregular densities generally distributed. Compatible with a diagnosis of pneumoconiosis but certainly not characteristic of exposure to fibrous silicates. There does

...SEE OTHER SIDE....

[illegible]: Examinee has well-advanced pulmonary emphysema by ventilation testing and by chest x-ray has significant pulmonary fibrosis.

...SEE OTHER SIDE...

[illegible]: 9/30/74

MLA/kl

Marvin L. [illegible]

CHEST X-RAY CONTINUED: not appear to be any pleural involvement. Trachea is in the midline. The diaphragms are reasonably smooth, present some minimal blunting and in the lateral projection are quite flat. The heart shadow does exhibit some minimal widening in the region of the thoracic aorta. The bony cage presents some emphysematous contour and in the lateral projection some increased areas of radiobility behind the sternum and behind the heart.

COMMENT: CONTINUED: It is not possible to exclude exposure to fibrous sillicates but this chest x-ray does not impress the examiner as being one of that class. I would suspect that this man may well have had prior occupational exposure and this will be investigated on the occasion of the re-examination next year. It should be noted that although there are marked changes by x-ray and ventilation study, the examinee does not allege any particular degree of disability.

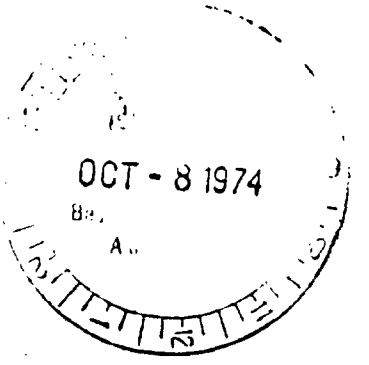

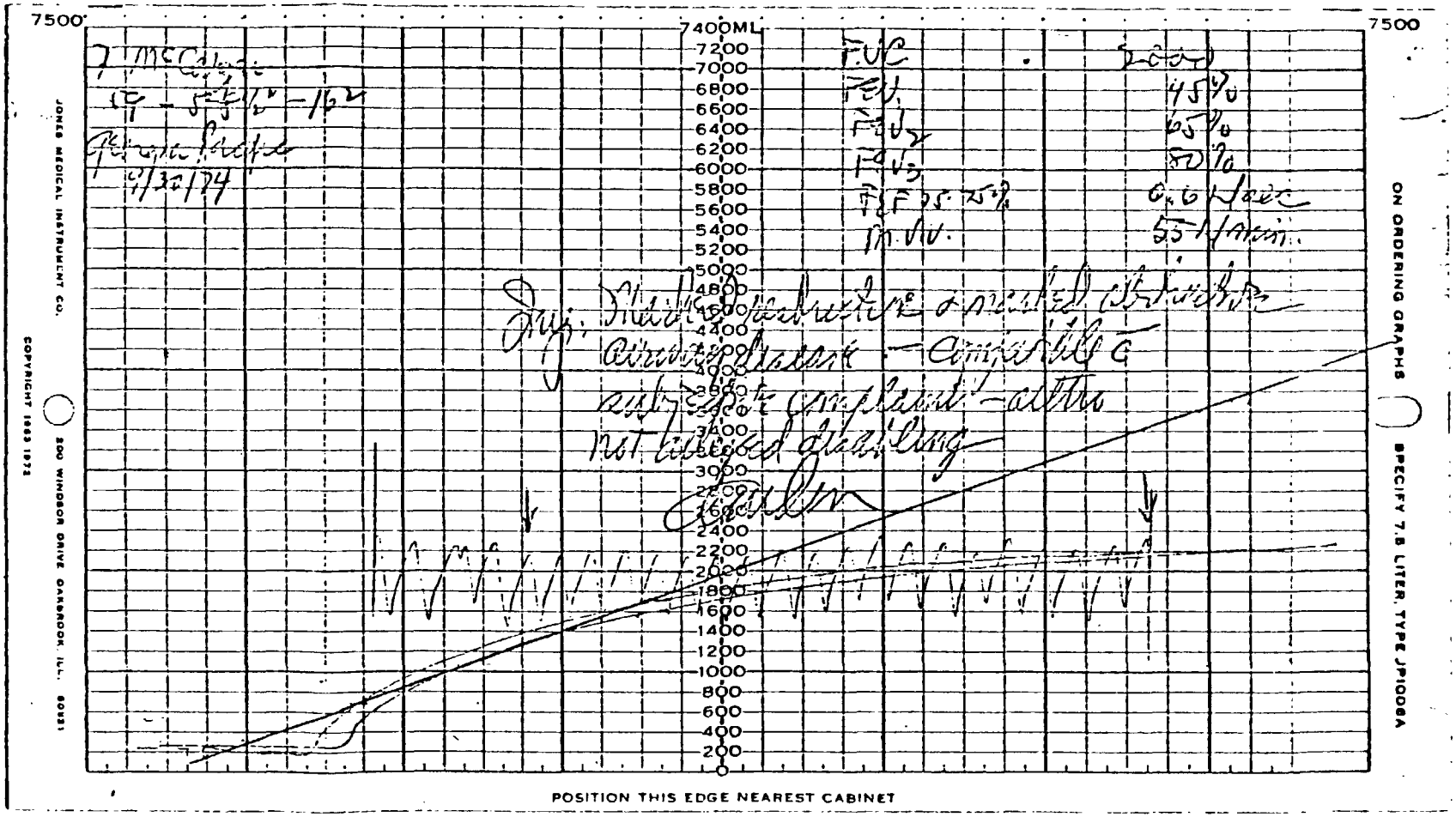
7500
7400ML
7200
7000
6800
6600
6400
6200
6000
5800
5600
5400
5200
5000
4800
4600
4400
4200
4000
3800
3600
3400
3200
3000
2800
2600
2400
2200
2000
1800
1600
1400
1200
1000
800
600
400
200
0
7500
FVC
FEV1
FEV2
FEV3
FEF25-75%
MVV
Pred
45%
65%
50%
0.6 L/sec
55 L/min
JONES MEDICAL INSTRUMENT CO.
COPYRIGHT 1968 1973
800 WINDSOR DRIVE OAKBROOK, ILL. 60521
ON ORDERING GRAPHS SPECIFY 7.8 LITER, TYPE JP100BA
POSITION THIS EDGE NEAREST CABINET

Walter Beglers 114-16-0655

[illegible]: 13418 [illegible] Rd [illegible]: 52

Akron Ohio

[illegible]: INDICATE [illegible]

1. [illegible]
2. [illegible] PAIN ✓
3. SHORT OF BREATH ✓
4. EXPECTORATION ✓
   BLOOD ✓
   AMOUNT/24 HRS.
   1 tsp.
   1 tbsp.
   1 cup
   1 cup
5. DO YOU SMOKE? no
   cigars/ /day
   pipe /month
   cigarettes
   pks/day /yrs.
   IF NO - [illegible]

no complaints -
no definite restrictions -

[illegible] IF YES - [illegible]

[illegible]	YES	NO
6. PNEUMONIA		✓
7. TUBERCULOSIS		✓
8. ASTHMA		✓
9. CHRONIC BRONCHITIS		
10. HEART DISEASE	✓	Heart attack 3 years ago no Rx
11. HIGH BLOOD PRESSURE		

[illegible]: [illegible]

Tracker 2 years (JT System Dept)

VENTILATION STUDY

FVC: 4200 cc
FEV1: 70%
FEV2: 85%
FEV3: 95%
FEF 25%-75%: 2L/sec.
M.V.V. 80 L/min.

[illegible]

Evidence of mild airway obstructive change probably not disabling.

SGP 0022081

[illegible]: 4008

Chest x-ray in multiple projections indicates normal root areas and peripheral lung fields. Trachea is in the midline. Heart shadow normal in size, position and configuration; though the diaphragms appear normal in the PA projection lateral projection does demonstrate distinct flattening with moderate accumulation of radiolucency in retrosternal area. Impression mild, nondisabling emphysema.

COMMENT: No subjective complaint. Mild ventilatory impairment. Chest x-ray suggests some emphysematous change.

[illegible]

DATE: 10/8/74

[signature] M.D.

JONES MEDICAL INSTRUMENT CO.
700 WINDSOR DRIVE OAKBROOK ILL. 60521
COPYRIGHT 1963 1973
7500
7400ML
7200
7000
6800
6600
6400
6200
6000
5800
5600
5400
5200
5000
4800
4600
4400
4200
4000
3800
3600
3400
3200
3000
2800
2600
2400
2200
2000
1800
1600
1400
1200
1000
800
600
400
200
0
POSITION THIS EDGE NEAREST EARTH'S
ON ORDERING GRAPHS SPECIFY 7.5 LITER TYPE JMC004A

SGP 0022082

NAME: [illegible] Soc. Sec.

Georgia-Pacific

[illegible]: 587

1. COUGH	yes	
2. CHEST PAIN		no
3. SHORT OF BREATH	yes	
4. EXPECTORATION		no
BLOODY		
AMOUNT/24 HRS.		
1 tsp.		
1 tbsp.		
1 cup		
1 cup		
5. DO YOU SMOKE?	yes	
cigars/ /day		
pipe /month		
cigarettes		
✓ 2 pks/day 35 /yrs.		
IF NO - HOW LONG		

Alleges cough and shortness of breath.

Also, note smoking history.

	YES	NO
6. PNEUMONIA		✓
7. TUBERCULOSIS		✓
8. ASTHMA		✓
9. CHRONIC BRONCHITIS	✓	
10. HEART DISEASE		✓
11. HIGH BLOOD PRESSURE		✓

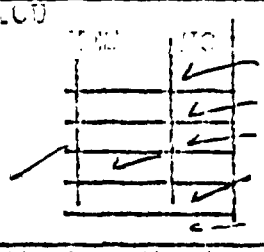

OCCUPATIONAL HISTORY: [illegible] HOW LONG HAVE [illegible]

WORK worked in Jt. Syst. for 3 yrs. on Ready Emp. 39 yrs at Geo. Pac.

VENTILATION STUDY

FVC:	2800 cc
FEV_1:	62%
FEV_2:	78%
FEV_3:	85%
FEF 25%-75%:	0.8 L/sec
M.V.V.	90 L/min

INTERPRETATION

Evidence of moderate restrictive and moderate airway obstructive disease.

SGP 0022083

[illegible]: 3838 #3838

The root areas are mildly prominent. There is noted to be some mild increase in radiability in both uppers. The horizontal fissure is slightly depressed upon the right. The lateral projection indicates moderate flattenning of both leaves of the diaphragm. Trachea is in the midline. There are proliferative changes over the dorsal spine. The heart shadow is normal.

COMMENT: Moderate evidence of pulmonary emphysema. Not particularly disabling.

[illegible]

DATE: 9/30/74

MLA/kl

Marvin L. Amdur, M. D.

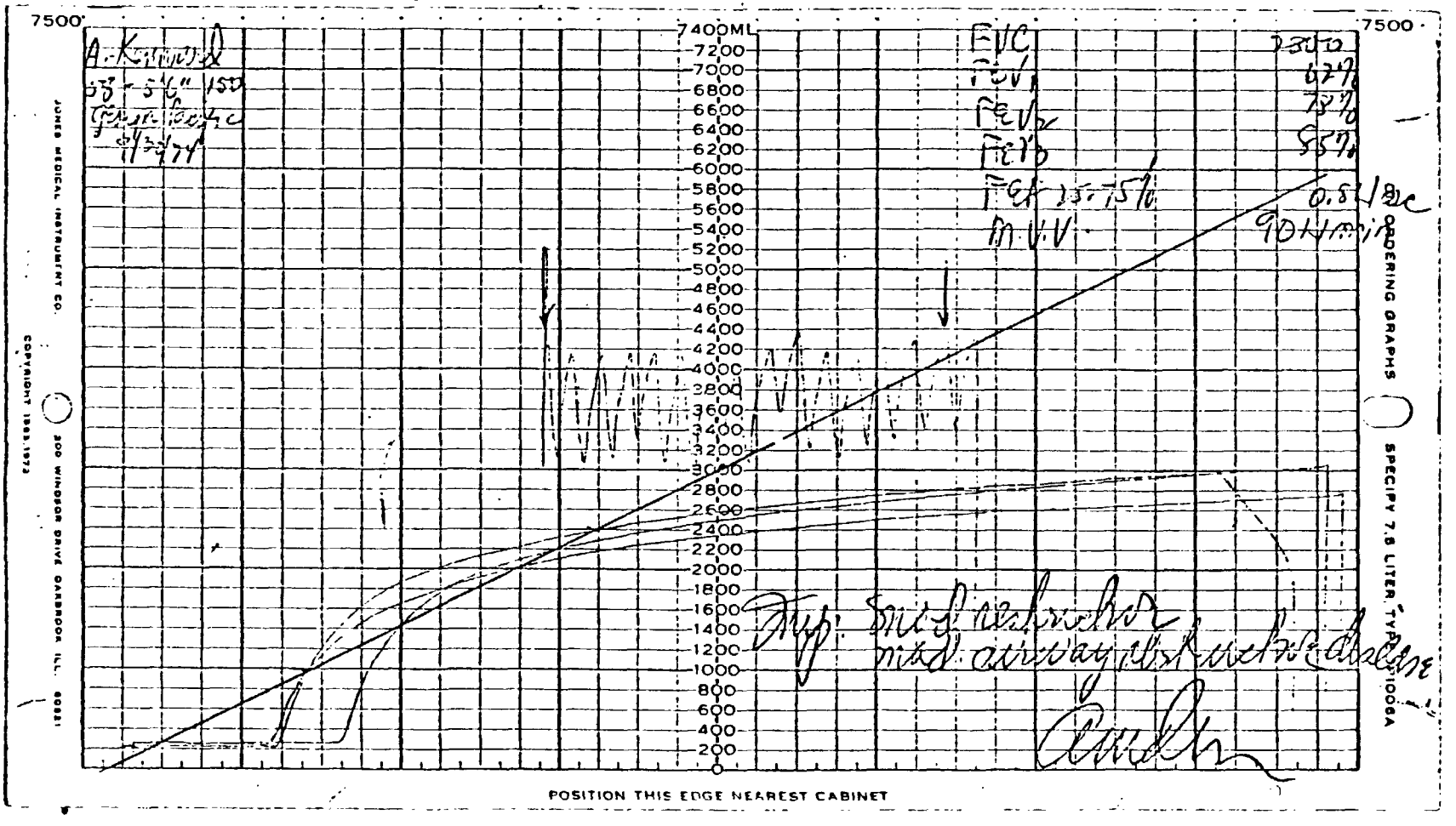
7500
7400ML
7200
7000
6800
6600
6400
6200
6000
5800
5600
5400
5200
5000
4800
4600
4400
4200
4000
3800
3600
3400
3200
3000
2800
2600
2400
2200
2000
1800
1600
1400
1200
1000
800
600
400
200
0
FVC
FEV1
FEV2
FEV3
FEF 25-75%
M.V.V.
0.8 L/sec
90 L/min
Typ. small reshuckor
mod. airway obstructive disease
JONES MEDICAL INSTRUMENT CO.
200 WINDSOR DRIVE OAKBROOK ILL. 60521
COPYRIGHT 1963-1972
ORDERING GRAPHS
SPECIFY 7.5 LITER TYPE 1006A
POSITION THIS EDGE NEAREST CABINET

SGP 0022084

[illegible] Pacific

NAME: Joseph John [illegible] 050-12-9735

[illegible]: 138 [illegible] 50 ✓

[illegible]

[illegible]: INDICATE

1. COUGH
2. CHEST PAIN ✓
3. SHORT OF BREATH ✓
4. EXPECTORATION ✓
   BLOOD ✓

AMOUNT/24 HRS.
1 tsp.
1 tbsp.
1 cup
1 cup

5. DO YOU SMOKE? ✓
   cigars/ /day
   pipe /month
   cigarettes 1½ /day /yrs.
   [illegible]

has cough & cold now -

[illegible]

	[illegible]	[illegible]
EVER HAD?		
6. PNEUMONIA		
7. TUBERCULOSIS		✓
8. ASTHMA		✓
9. CHRONIC BRONCHITIS		✓
10. HEART DISEASE		✓
11. HIGH BLOOD PRESSURE		✓

[illegible]

[illegible]: Yardman now 2 wk - trucker 2½ yrs at Joint System

VENTILATION STUDY

FVC: 4200 cc
FEV1: 65%
FEV2: 82%
FEV3: 95%
FEF 25%-75%: 1.5 L/sec
[illegible]: 100 L/min

[illegible]

Mild airway obstructive change.

[illegible]: 4004

Mild prominence of the root areas, some increase in markings in both lower lobes. Heart shadow is normal. Bony cage exhibits some emphysematous configuration with some evidence of increased radiability behind the sternum. Impression minimal emphysema.

SGP 0022085

[illegible]: Absence subjective complaint. Ventilation studies indicate mild defect. Chest x-ray confirms minimal evidence of emphysema probably not disabling.

[illegible]

DATE: 10/5/74

[signature] M.D.

JONES MEDICAL INSTRUMENT CO. 200 WINDSOR DRIVE, OAKBROOK ILL. 60521
COPYRIGHT 1963 1973
7500
7400 ML
7200
7000
6800
6600
6400
6200
6000
5800
5600
5400
5200
5000
4800
4600
4400
4200
4000
3800
3600
3400
3200
3000
2800
2600
2400
2200
2000
1800
1600
1400
1200
1000
800
600
400
200
POSITION THIS EDGE NEAREST CABINET
ON ORDERING GRAPE SPECIFY 7.5 LITER TYPE JP100BA
7500

SGP 0022086

RIBBECK, Charles Employed: GEORGIA-PACIFIC

NAME Charles F Ribbeck Soc. Sec. # 118-05-5411

ADDRESS AKRON RFD-1 Oregon Road Age: 61 MXF

COPY

1. COUGH	yes	
2. CHEST PAIN		no
3. SHORT OF BREATH	yes	
4. EXPECTORATION		
BLOOD		no
AMOUNT/24 HRS.		
1 tsp.		
1 tbsp.		
1 cup		
1 cup		
5. [illegible]	yes	
cigars/		
[illegible]	1 pack	
[illegible]	3 D [illegible]	
1/3 [illegible]	.45 yrs	

under care Dr Lengner for emphysema past two years also diabetic 1980 42 U daily also taking digitalis & diuretic for cardiac complaint.

6. [illegible]		✓
7. [illegible]		✓
8. [illegible]		✓
9. CHRONIC BRONCHITIS		✓
10. HEART DISEASE	✓	✓
11. [illegible]		

Worked in Jt-Syst Dept for 2 yrs. 26 yrs for Geo. Pac.

FVC:	1700cc
FEV1:	60%
FEV2:	78%
FEV3:	90%
[illegible]:	0.5L/sec
[illegible]	50L/min

There is gross evidence of restrictive parenchymal disease and evidence of of substantial airway obstructive disease.

RECEIVED OCT 14 1974 Bestwall Gypsum Co. Akron, N.Y.

SGP 0022087

[illegible]: 3890 #3890

Moderate prominence of both root areas. Some general increase in bronchovascular markings throughout all lobes. Horizontal fissure is noted in the usual position on the right. Some increased radiobility in both bases. The lateral projection indicates mild enlargement of the cardiac shadow posteriorly. Some increase in radiobility behind the sternum. There is but minimal flattening of the diaphragms in the lateral

....SEE REVERSE....

[illegible]: Examinee has a clinical diagnosis of emphysema and is evidently being treated for this by his personal physician. It may well

CONT'D ON REVERSE...

[illegible]: 10-2-74

MLA/kl
Atach.

Marvin L. Amdur, M. D.

CHEST X-RAY #3890 - Cont'd: projection. Heart shadow is otherwise not abnormal. The bony cage is normal.

COMMENT - Cont'd: be that his pulmonary emphysema is not particularly disabling but his associated cardiac difficulties are. There is nothing in the chest x-ray which would indicate that he has an occupational fibrosis. Certainly nothing to suggest that any fibrous silicate (asbestos) is causally related to his present complaint. See attached blood gas studies. Examinee should be under continued medical surveillance.

ATTACHED BLOOD GAS REPORT THOUGH INDICATING A MILD LOWERING OF ARTERIAL OXYGEN TENSION ACTUALLY IS NOT PARTICULARLY ABNORMAL FOR EXAMINEE'S AGE. MILD COMPENSATORY ALKALOSIS IS A NATURAL CONCOMITTANT OF EVIDENT MILD HYPERVENTILATION.
OVERALL IMPRESSION I STHAT OF MILD PULMONARY DISABILITY DUE TO EMPHYSEMA - ETIOLOGY OTHERWISE NOT IDENTIFIED

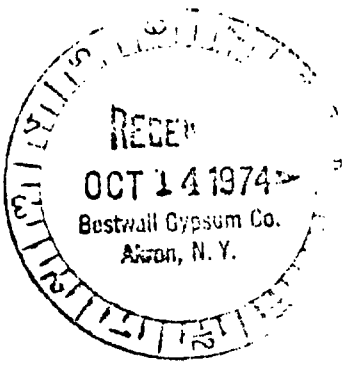

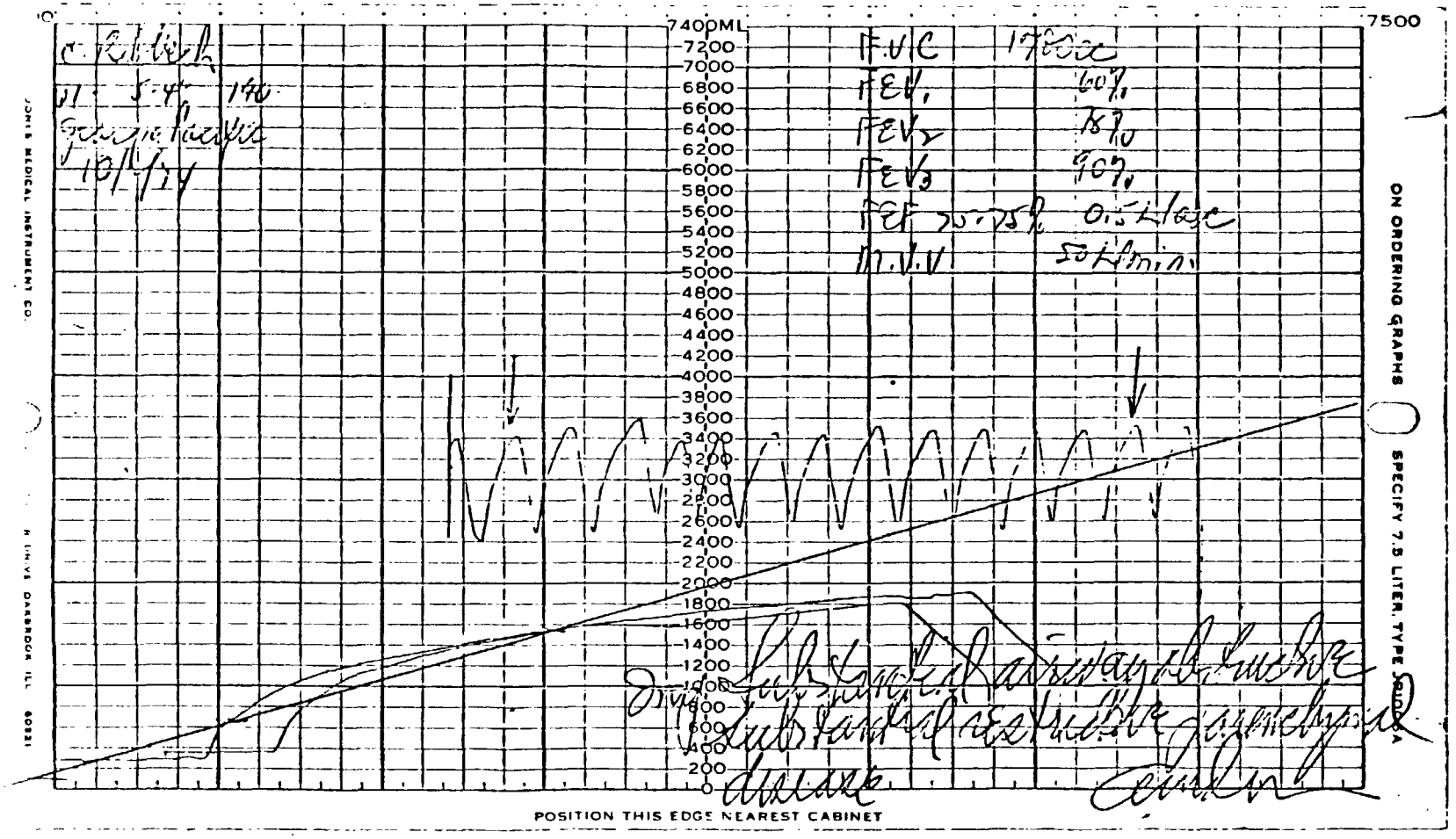

SGP 0022089

REC'D OCT 14 1974 Restw... Co.

KENMORE MERCY HOSPITAL

PULMONARY FUNCTION LABORATORY

PATIENT Rubbeck Charles

DATE 10 [illegible] 74

ROOM # OP

TIME 2 PM

DOCTOR Amber

O_2 THERAPY

SOURCE OF BLOOD Arterial

COPY

ACID - BASE STUDY (Astrup Method)

		Normal (arterial)		Actual
1.	PH	7.40	±0.03	7.44
2.	PCO_2	40 mm Hg	± 4	44 mmHg
3.	STD BICARB	24 meq/l	± 2	28 meq/l
4.	BASE EXCESS	0 meq/l	± 2.5	+5 meq/l
5.	BUFFER BASE	46 meq/l	± 5	53 meq/l

OXYGEN TENSION

Normal (Arterial)	Actu
PO_2----80-100mm Hg	40 mm

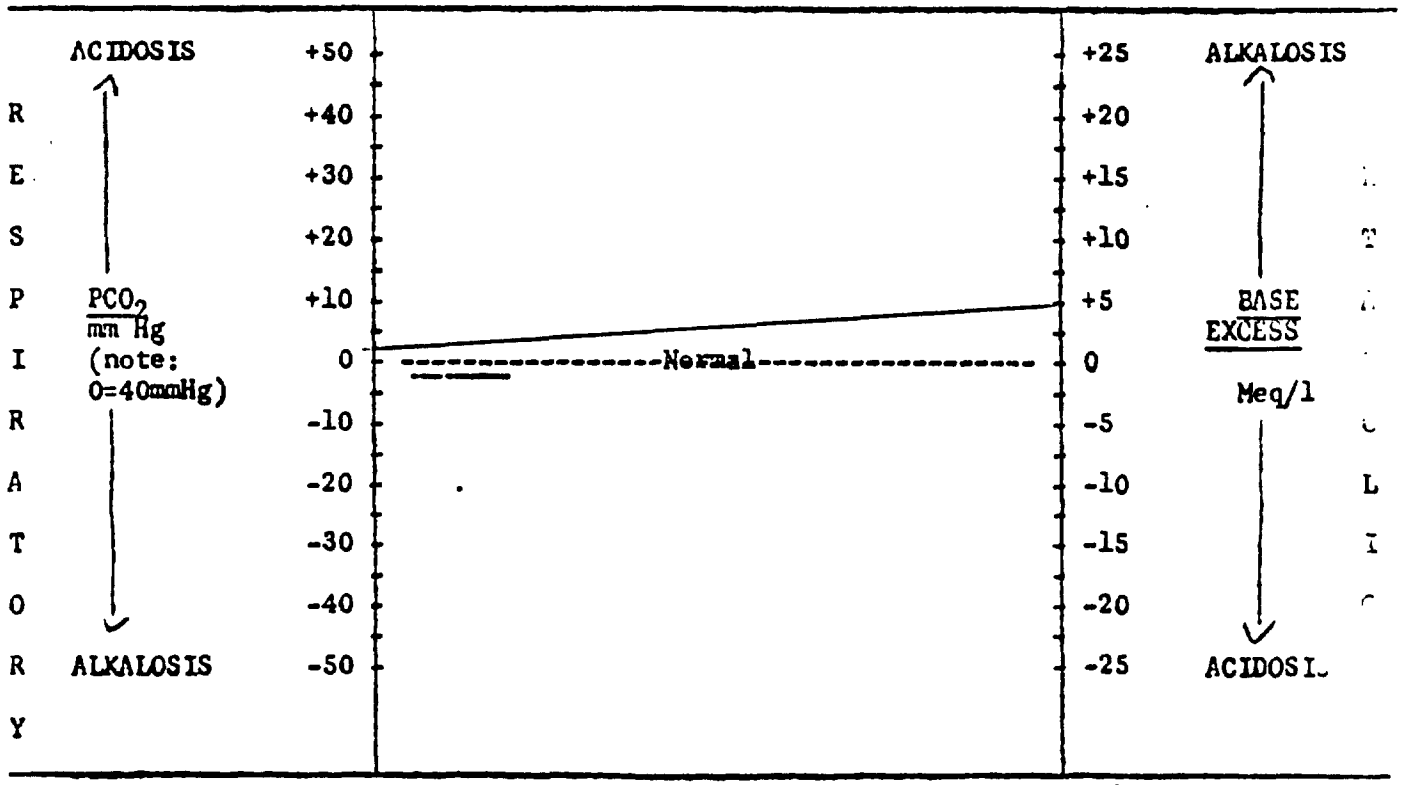

TECHNICIAN [illegible]
Carol Lingel

RECE
OCT 14 1974
Bestwall Gypsum Co.
Akron, N. Y.

F.Beerel, M.D.

SGP 0022090

L. RIBBECK 115-16-4477
15 LEWIS RD. 48 X
AKRON, N.Y.

Examinee has no subjective complaints whatsoever and medical history is noted to be negative.

1 26

JOINT SYSTEM MECHANICS
1 1/2 YEARS

VENTILATION STUDY

FVC: 2800cc
FEV1: 70%
FEV2: 86%
FEV3: 95%
FEF 25%-75%: 1.75L/sec
[illegible] 50L/min

Values are low suggesting mild to moderate restrictive and some evidence of obstructive airway disease. Entire response is probably a reflection of inadequate effort in energy dependent test.

4006

Mild prominence of the root areas. Peripheral lung fields are generally not remarkable. The lateral view likewise demonstrates no significant evidence of disease.

SGP 0022091

History and chest x-ray are satisfactory. Ventilation studies would suggest [illegible] some defect, referred for blood gas studies. (SEE Attached)

10/5/74

JONES MEDICAL INSTRUMENT CO.
700 WINDSOR DRIVE OAKBROOK ILL. 60521
COPYRIGHT 1963 1973
7500
7400 ML
7200
7000
6800
6600
6400
6200
6000
5800
5600
5400
5200
5000
4800
4600
4400
4200
4000
3800
3600
3400
3200
3000
2800
2600
2400
2200
2000
1800
1600
1400
1200
1000
800
600
400
200
0
POSITION THIS EDGE NEAREST CABINET
ON ORDERING GRAPHS
SPECIFY 7.3 LITER TYPE JP1003A
7500

SGP 0022092

PATIENT Robert Lawrence DOCTOR Amdur / Strachan

ROOM # 0?

KENMORE MERCY HOSPITAL
PULMONARY FUNCTION LABORATORY
ACTUAL VALUES

NORMAL ARTERIAL VALUES		#1	#2	#3	#4	#5	#6
Day		10-8-74					
Time		NOON					
Source		ART					
A. Oxygen Tension PO_2 80 - 100 mm Hg		75					
Oxygen Therapy ____							
B. Acid Base Study (Astrup) PH	7.40 ± 0.03	7.41					
PCO_2	40 ± 4 mmHg	32					
Std HCO_3	24 + 2meq/L	21.5					
Base Exc.	0 ± 2.5meq/L	-3					
Buffer Base	46 ± 5meq/L	47					

FINDINGS OF A MILD RESPIRATORY ALKALOSIS IS COMPATIBLE WITH MILD PULMONARY DISABILITY BUT WITH ADEQAUTE COMPENSATION BY VIRTUE OF INCREASED RESPIRATORY RATE. PROBABLY REQUIRES NO TREATMENT - PLEASE ADVISE EXAMINEE

Amdur

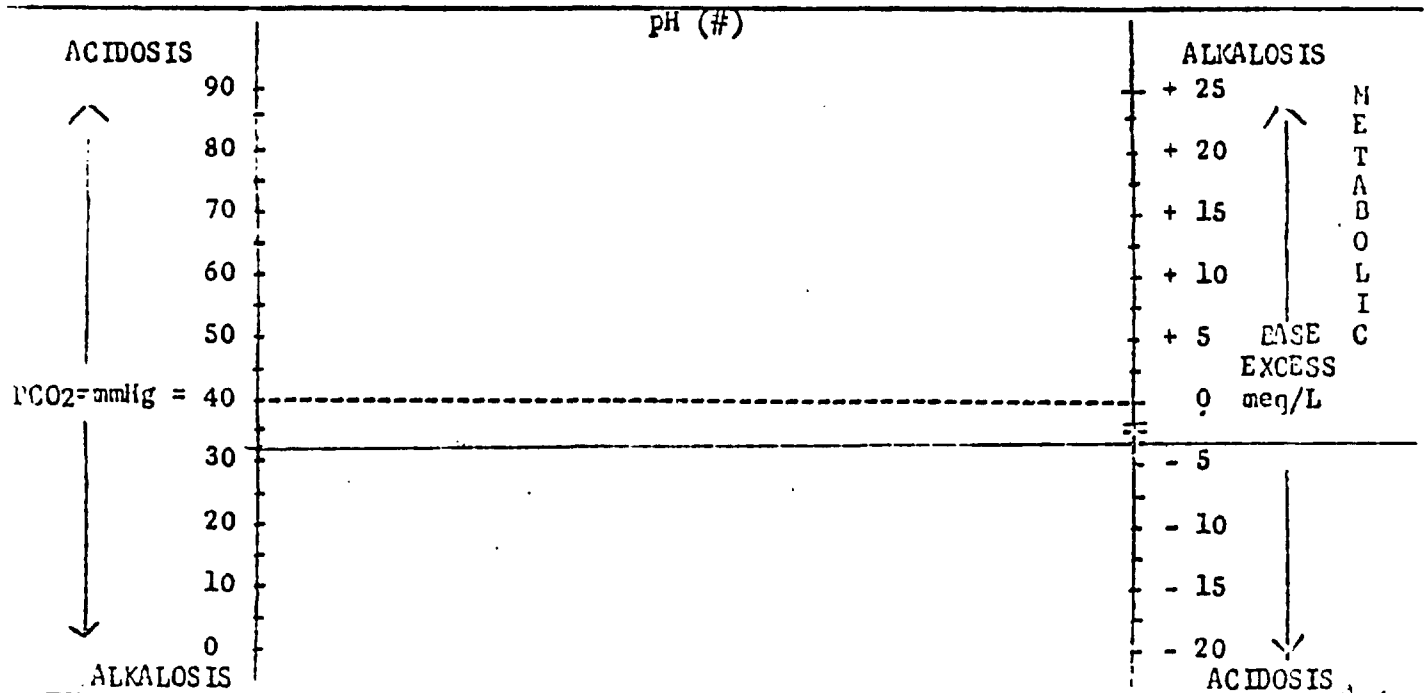

DATE 10/8/74 INTERPRETATION: Mild respiratory alkalosis

SGP 0022093

Leslie Quackenbush : 38 119 25-0540

RED 2 Middleport, NY

Stopped Smoking
1 yr ago - Prev. 1½ ph/day/9 y
Has had Steroid Rx for asthma - none past ten years

10-25-63

Dr. Hans Lowenstein Middleport, NY

work 20 years parker Stacker

VENTILATION STUDY

FVC:	4000cc
FEV1:	78%
FEV2:	90%
FEV3:	100%
FEF 25%-75%:	2.25 L/sec
M.V.V.	110 L/min

Quite satisfactory. No evidence of either obstructive airway disease or restrictive parenchymal disease.

SGP 0022094

3839 #3839

Moderate prominence of both root areas. Some general increase in broncho-vascular markings into both lower lobes. No evidence of specific parenchymal disease. No evidence of pleural disease. Heart shadow is normal in size and position. There appears to be some peculiar expansion superiorly but this may be sternal shadow. It certainly is not a reflection of lung pathology.

History of asthma with steroid treatment noted. No evidence of any disability at this time directed to the chest. Ventilation studies are quite satisfactory.

9/30/74

MLA/kl

Marvin L. Amdur, M. D.

JONES MEDICAL INSTRUMENT CO.
300 WINDSOR DRIVE, OAKBROOK, ILL. 60521
COPYRIGHT 1963, 1972
7500
7400ML
7200
7000
6800
6600
6400
6200
6000
5800
5600
5400
5200
5000
4800
4600
4400
4200
4000
3800
3600
3400
3200
3000
2800
2600
2400
2200
2000
1800
1600
1400
1200
1000
800
600
400
200
0
POSITION THIS EDGE NEAREST CABINET
ON ORDERING DRAWING
PRECIPY 7.5 LITER, TYPE JPIOOOA
7500

SGP 0022095

GEORGIA - PACIFIC

NAME: LAVERNE P. LEE SOC. SEC. NO. 062-12-6033
ADDRESS: 13575 Bloomingdale Rd. AGE: 54 M/F
Akron N.Y. 14001

EMPLOYEE: INDICATE YES/NO

1.COUGH	
2.CHEST PAIN	No
3.SHORT OF BREATH	No
4.EXPECTORATION	No
BLOOD?	No

AMOUNT/24 HRS.
1 tsp.
1 tbsp.
¼ cup
½ cup

5.DO YOU SMOKE? No
cigars/ /day
pipe /month
cigarettes
pks/day / /yrs.
IF NO - HOW LONG

NO SUBJECTIVE COMPLAINT.

DO YOU NOW HAVE OR HAVE YOU EVER HAD?	YES	NO	IF YES - DESCRIBE
6.PNEUMONIA		No	Every so often get wheezing spells
7.TUBERCULOSIS		No	
8.ASTHMA		No	
9.CHRONIC BRONCHITIS	Yes		
10.HEART DISEASE		No	
11.HIGH BLOOD PRESSURE			

OCCUPATIONAL HISTORY: WHAT DO YOU DO AND HOW LONG HAVE YOU DONE IT?
Truck Driver 11 months
in Joint System

VENTILATION STUDY

FVC:	2600 cc
FEV_1:	80 %
FEV_2:	100 %
FEV_3:	100 %
FEF 25%-75%:	1.8 L/Sec
M.V.V.	60 L/min

INTERPRETATION

Moderate restriction - both as to total volume and ability to ventilate maximally suggests some defect but probably this is directed more to the examinee's obesity than it is to any evident pulmonary difficulty.

SGP 0022096

X-RAY OF CHEST FILM NUMBER: 4274 #4274

Mild promimence of the root areas. Minimal increase in broncho-vascular markings throughout all lobes but no evidence of any specific parenchymatous disease. Heart shadow and bony cage are normal. Narrow configuration of the chest indicating failure to fully inflate suggests the effect of obesity.

COMMENT: General health status seems satisfactory with regard to chest. I suspect that obesity may be responsible for any subjective complaint.

BUFFALO INDUSTRIAL MEDICAL CENTER

DATE: 10/23/74

Maurice L. Lewis

RECEIVED OCT 29 1974 Bestwall Gypsum Co Akron, N.Y.

REC'D
OCT 29 1974
Bestwall Gypsum Co
Akron

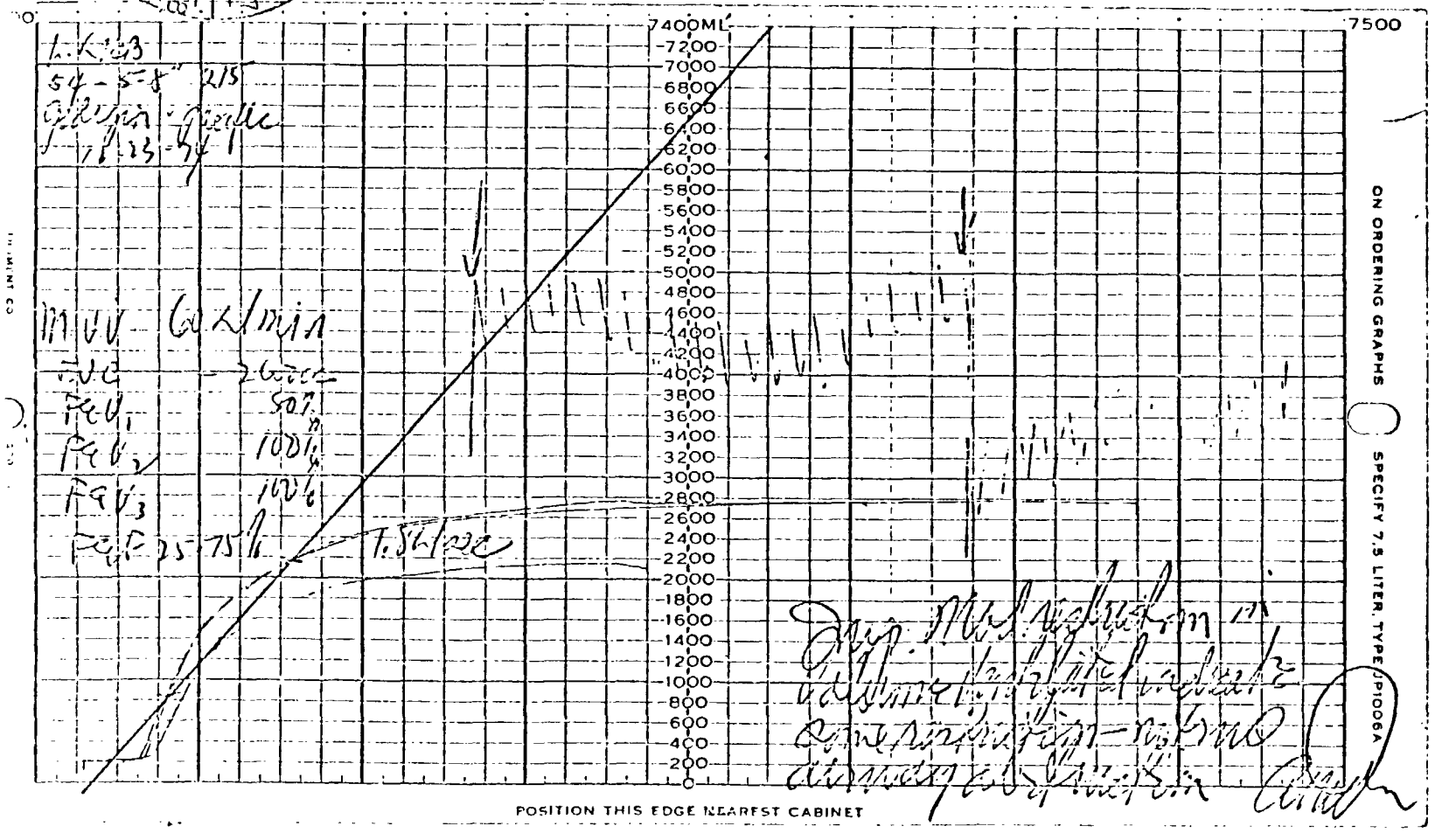

SGP 0022097

[illegible]: JOHN G DARMSTEDTER [illegible] 084-24-460
[illegible]: 24 ALBERT CT [illegible]: 43 ✓
DEPEW, NY 14043

[illegible]: INDICATE [illegible]

1. COUGH		✓
2. CHEST PAIN		✓
3. SHORT OF BREATH		✓
4. EXPECTORATION		
BLOODY		✓

AMOUNT/24 HRS.
1 tsp.
1 tbsp.
1 cup
1 cup

5. DO YOU SMOKE? ✓
cigars/ /day
pipe /month
cigarettes
1 pks/day 20/yrs.
IF [illegible]

Satisfactory
Inquiry

DO YOU [illegible] HAVE OR HAVE YOU [illegible] HAD?

	YES	NO
6. PNEUMONIA	✓	
7. TUBERCULOSIS		✓
8. ASTHMA		✓
9. CHRONIC BRONCHITIS		✓
10. HEART DISEASE		✓
11. HIGH BLOOD PRESSURE		✓

IF YES - [illegible]
IN 1953 IN ARMY

OCCUPATIONAL HISTORY: [illegible] DO YOU DO AND HOW LONG HAVE YOU [illegible]

QUALITY CONTROL SUPT 15 YRS

VENTILATION STUDY

FVC: 5600 cc
FEV_1: 75%
FEV_2: 88%
FEV_3: 100%
FEF 25%-75%: 3 L/sec
M.V.V. 128 L/min

[illegible]

Satisfactory.

[illegible] OF CHEST FILM NUMBER: 3971

Mild prominence of the root areas, some general increase in bronchovascular markings throughout all lobes but no evidence of specific parenchymatous disease. Trachea is in the midline. Diaphragms are smooth and sulci are clear. Heart shadow, bony cage are normal.

Impression: Chest x-ray satisfactory and compatible with examinee's age.
Ventilation studies satisfactory. Chest x-ray likewise satisfactory.
[illegible]: Impression: Overall status is good.

[illegible]
DATE: 10/7/94

[signature]

SGP 0022098

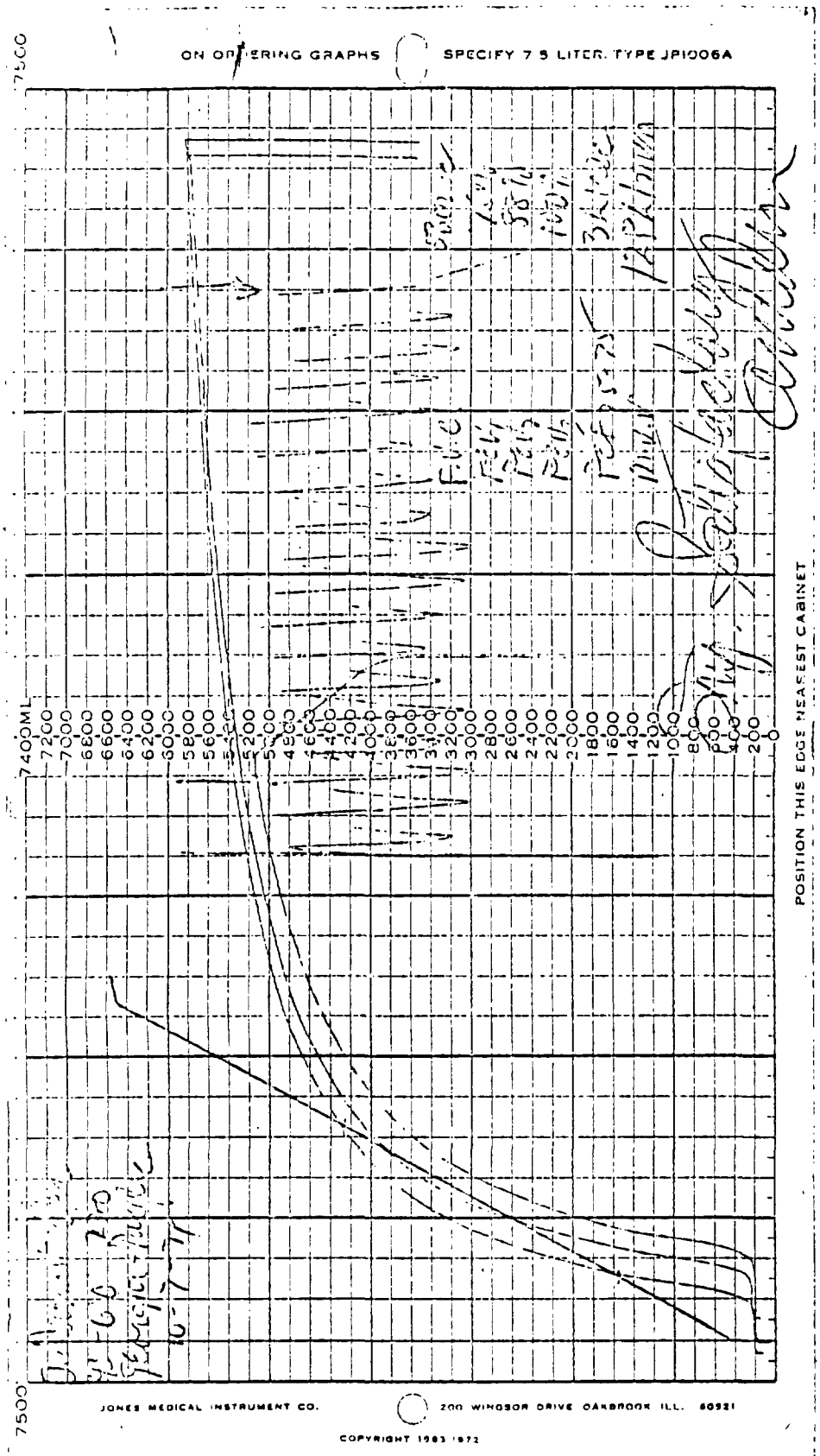
ON ORDERING GRAPHS SPECIFY 7.5 LITER. TYPE JP1006A
7500
7400ML
7200
7000
6800
6600
6400
6200
6000
5800
5600
5400
5200
5000
4800
4600
4400
4200
4000
3800
3600
3400
3200
3000
2800
2600
2400
2200
2000
1800
1600
1400
1200
1000
800
600
400
200
0
7500
POSITION THIS EDGE NEAREST CABINET
JONES MEDICAL INSTRUMENT CO.
200 WINDSOR DRIVE OAKBROOK ILL. 60521
COPYRIGHT 1963 1972

SGP 0022099

COMMENT - Cont'd: and I would appreciate an opportunity to repeat the chest x-ray to be certain that the finding demonstrated at this time is artificial and not within the lung fields.



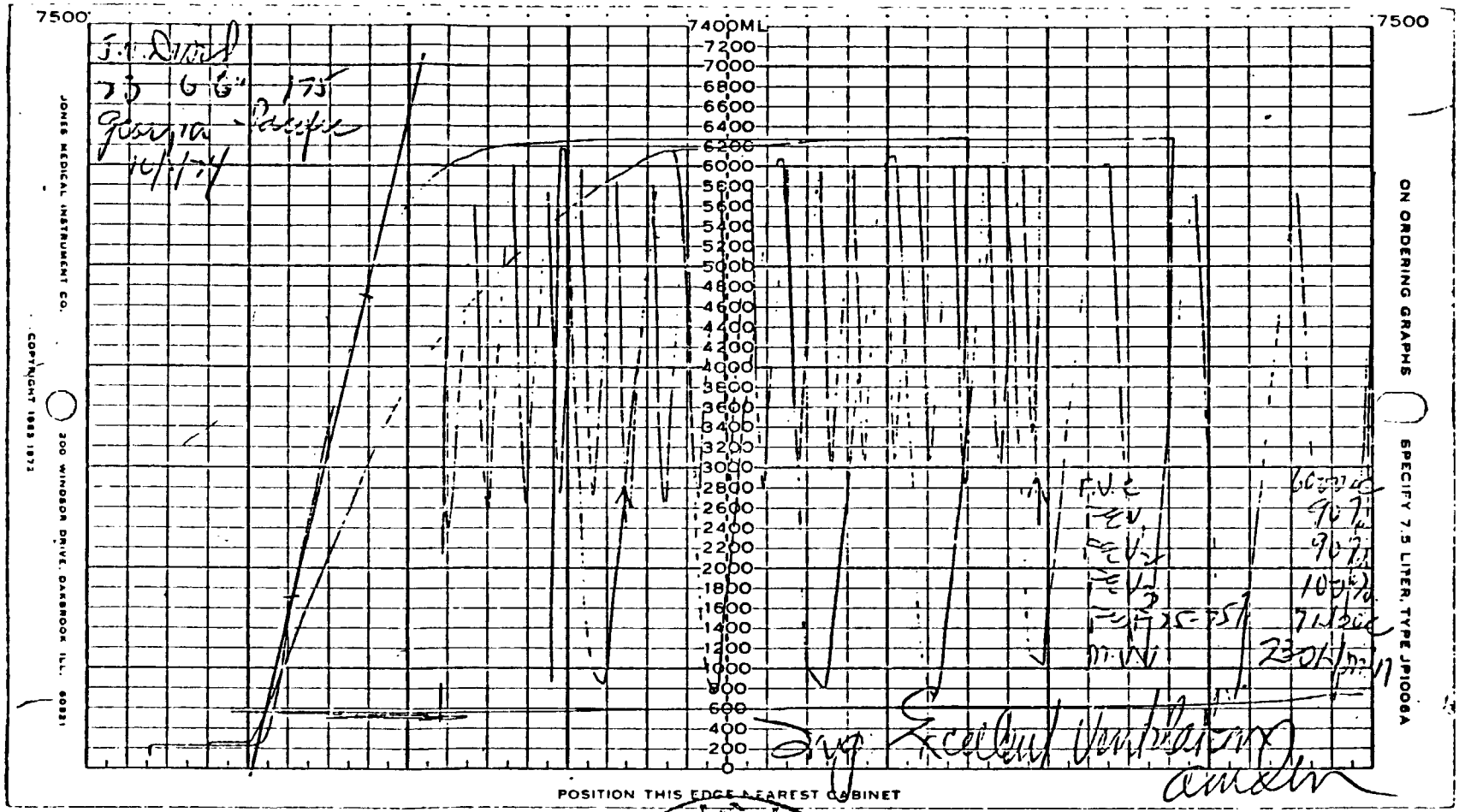

RECD.
OCT 14 1974
Bestwall Gypsum Co.
Akron, N.Y.

SGP 0022101

MARVIN L. AMDUR M.D.
ROBERT A. CAPUTI, M.D.
HAROLD L. GRAFF, M.D.
JOHN N. STRACHAN, M.D.

BUFFALO INDUSTRIAL HYGIENE
LABORATORIES

BUFFALO INDUSTRIAL MEDICAL CENTER
755 TONAWANDA STREET
BUFFALO, N. Y. 14207
TELEPHONE: 875-1514

October 5th, 1974

Memo:

Mr. Schifferle
Georgia-Pacific

Re: DAVID, James W.
13869 Bloomingdale Road
Akron, New York

Chest x-ray #3898 - 10/2/74

Dear Sir:

Reviewing this chest x-ray suggests that there is a defect probably in the film and in the interests of diligence, I would appreciate an opportunity to repeat this chest x-ray.

Very truly yours,

Marvin L. Amdur, M. D.

MLA/kl



DAVID, James W. Employed: GEORGIA-PACIFIC

James W DAVID 115-44-3820

13869 Bloomingdale Rd. 23 X

AKRON N.Y.

1. COUGH		
2. CHEST PAIN	✓	
3. SHORT OF BREATH	✓	
4. EXPECTORATION	✓	
BLOODY		✓

AMOUNT/24 HRS.
1 tsp.
1 tbsp.
1 cup
1 cup

5. DO YOU SMOKE? yes
cigars/ /day
/month
cigarettes
1½ [illegible] 14 [illegible]

no complaints

6. PNEUMONIA		✓
7. TUBERCULOSIS		✓
8. ASTHMA		✓
9. CHRONIC BRONCHITIS		✓
10. HEART DISEASE		✓
11. HIGH BLOOD PRESSURE		✓

OCCUPATIONAL HISTORY: WHAT DO YOU DO AND HOW LONG HAVE YOU WORK

Joint System

VENTILATION STUDY

FVC: 6000cc
FEV1: 90%
FEV2: 90%
FEV3: 100%
FEF 25%-75%: 7L/sec
M.V... 230L/min

INTERPRETATION
Excellent level of function.

RECEIVED OCT 14 1974 Bestwall Gypsum Co. Akron, N.Y.

SGP 0022103

WHAT OF CHEST FILM NUMBER: 3898 #3898

The root areas are entirely normal. In the periphery of the right 3rd interspace there appears to be some area of density but I suspect that this is probably an artifact and that it does not represent parenchymal disease. The lung fields are otherwise quite satisfactory. Trachea is in the midline. Diaphragms are smooth and all sulci are clear. Heart shadow and bony cage are normal.

COMMENT: I find nothing to suggest any diseased state. The ventilation studies are normal. Chest x-ray, I suspect, is likewise normal. The area referred to in the right chest is probably an artifact.... CONT'D REVERSE...

10/2/74
MLA/kl

Marvin L. Amdur, M. D.

M.D.
ROBERT A. CAPUTI, M.D
HAROLD L. GRAFF, M.D.
JOHN N. STRACHAN, M.D.

Telephone

BUFFALO INDUSTRIAL MEDICAL CENTER
755 TONAWANDA STREET
BUFFALO, N.Y. 14207

X-RAY REPORT

NAME DAVID, James EMPLOYER Georgia-Pacific

ADDRESS 13869 Bloomingdale Rd., Akron, N.Y. INS. CARRIER

Date 10/23/74 Part Examined #4275 - Chest Film No. #4275

Radiographic Findings:

Repeat chest x-ray, in accordance with prior report, does not indicate same abnormality previously described as being present in the right upper lobe. It is the impression of this examiner, therefore, that the original defect was probably an artifact and that the examinee's chest x-ray is quite satisfactory.

MLA/kl

REC'D
OCT 29 1974
Bestwall Gypsum Co
Akron, N.Y.

Marvin L. Amdur, M. D.
M.D.

SGP 0022104

Employed Georgia Pacific

[illegible]: Raymond C. Fisher [illegible]

[illegible]: 13555 [illegible] [illegible]: 25 [illegible]

Akron, Ohio 1400[illegible]

[illegible]: [illegible]

1. COUGH
2. CHEST PAIN ✓
3. SHORT OF BREATH ✓
4. EXPECTORATION ✓
   BLOODY ✓
   AMOUNT/24 HRS.
   1 tsp.
   1 tbsp.
   1 cup
   1 cup
5. DO YOU SMOKE? 1 ns
   cigars/ /day
   pipe /month
   cigarettes
   [illegible]/day /yrs.
   [illegible]

No complaints

[illegible]

[illegible]

[illegible]

[illegible]

[illegible]

[illegible]

[illegible]

[illegible]

[illegible]

[illegible]

Plant work 4 yrs

VENTILATION STUDY

FVC: 4200 cc
FEV1: 90%
FEV2: 100%
FEV3: 100%
FEF 25-75: 6 L/sec
[illegible] 105 L/min

[illegible]

Ventilation studies quite satisfactory.

[illegible]: 3974

Mild prominence of both root areas. Peripheral lung fields are entirely normal. Trachea is in the midline. Diaphragms are smooth and sulci are clear. No evidence of any pleural reaction. Heart shadow and bony cage are normal.

Impression normal chest.

SGP 0022105

[illegible]: There are no physical complaints. Ventilation study and chest x-ray are quite satisfactory.

[illegible]

[illegible]: 6/7/74

[illegible]


ON ORDERING GRAPHS SPECIFY 7.5 LITER. TYPE JP1006A
7500
7400ML
7200
7000
6800
6600
6400
6200
6000
5800
5600
5400
5200
5000
4800
4600
4400
4200
4000
3800
3600
3400
3200
3000
2800
2600
2400
2200
2000
1800
1600
1400
1200
1000
800
600
400
200
0
POSITION THIS EDGE NEAREST CABINET
JONES MEDICAL INSTRUMENT CO.
200 WINDSOR DRIVE, OAKBROOK ILL. 60521
COPYRIGHT 1963 1972

SGP 0022106

Employed Georgia Pacific

Arnold J. Handrich

[illegible] AGE: 43 [illegible]

[illegible]

[illegible]

[illegible] 6 mo.

[illegible]

[illegible] (G.P. 22 yrs.) trucker & packer stacker joint system [illegible]

VENTILATION STUDY	[illegible]
FVC: 5000 cc FEV1: 80% FEV2: 95% FEV3: 100% FEF 25%-75%: 3.5 L/sec [illegible] 120 L/min	Ventilation study quite satisfactory.

[illegible]: 3970

The root areas and peripheral lung fields are entirely normal beyond some minimal increase in markings in the right lower lobe. No evidence of pleural changes. Heart shadow, bony cage are normal.

General impression is that of a satisfactory chest x-ray.

SGP 0022107

[illegible]: No evidence objective complaint. Chest x-ray and ventilation studies are normal.

[illegible]

[illegible]: 10/7/74

[illegible]


7500
7400ML
7200
7000
6800
6600
6400
6200
6000
5800
5600
5400
5200
5000
4800
4600
4400
4200
4000
3800
3600
3400
3200
3000
2800
2600
2400
2200
2000
1800
1600
1400
1200
1000
800
600
400
200
0
7500
JOYCE MEDICAL INSTRUMENT CO.
200 WINDSOR DRIVE, OAKBROOK ILL. 60521
COPYRIGHT 1963 1972
ON ORDERING GRAPHS
SPECIFY 7.5 LITER, TYPE JRIGGA
POSITION THIS EDGE NEAREST CABINET

SGP 0022108

NAME Alton Hosts SOC. SEC. # 095-03-1125

69 Minard St. 63

Lockport N.Y. 14094

	YES	NO
[illegible]	✓	
[illegible]		
[illegible]	✓	
[illegible]		
[illegible]	✓	

Note: Some complaint of chest pain and expectoration. Examinee has been smoking for many years.

[illegible] 40 [illegible]

[illegible]		✓
[illegible]		✓
[illegible]		✓
[illegible]		✓
[illegible]		✓
[illegible]		✓

General Plant work Joint System 39 yrs

VENTILATION STUDY

FVC: 4200cc
FEV1: 80%
FEV2: 90%
FEV3: 96%
FEF 25%-75%: 3 L/sec
P.V.V. 75 L/min

Quite satisfactory for the examinee's age. No significant evidence of either restrictive or obstructive disease.

[illegible] 3841 #3841

Moderate prominence of the right root with increased bronchovascular markings throughout the lower halves of both lung fields. Heart shadow and bony cage are normal.

SGP 0022109

Chest x-ray and ventilation studies compatible with examinee's age. No particular evidence of any pulmonary disability.

[illegible] 9/30/74

MLA/kl

Marvin L. Amdur, M. D.

SGP 0022110

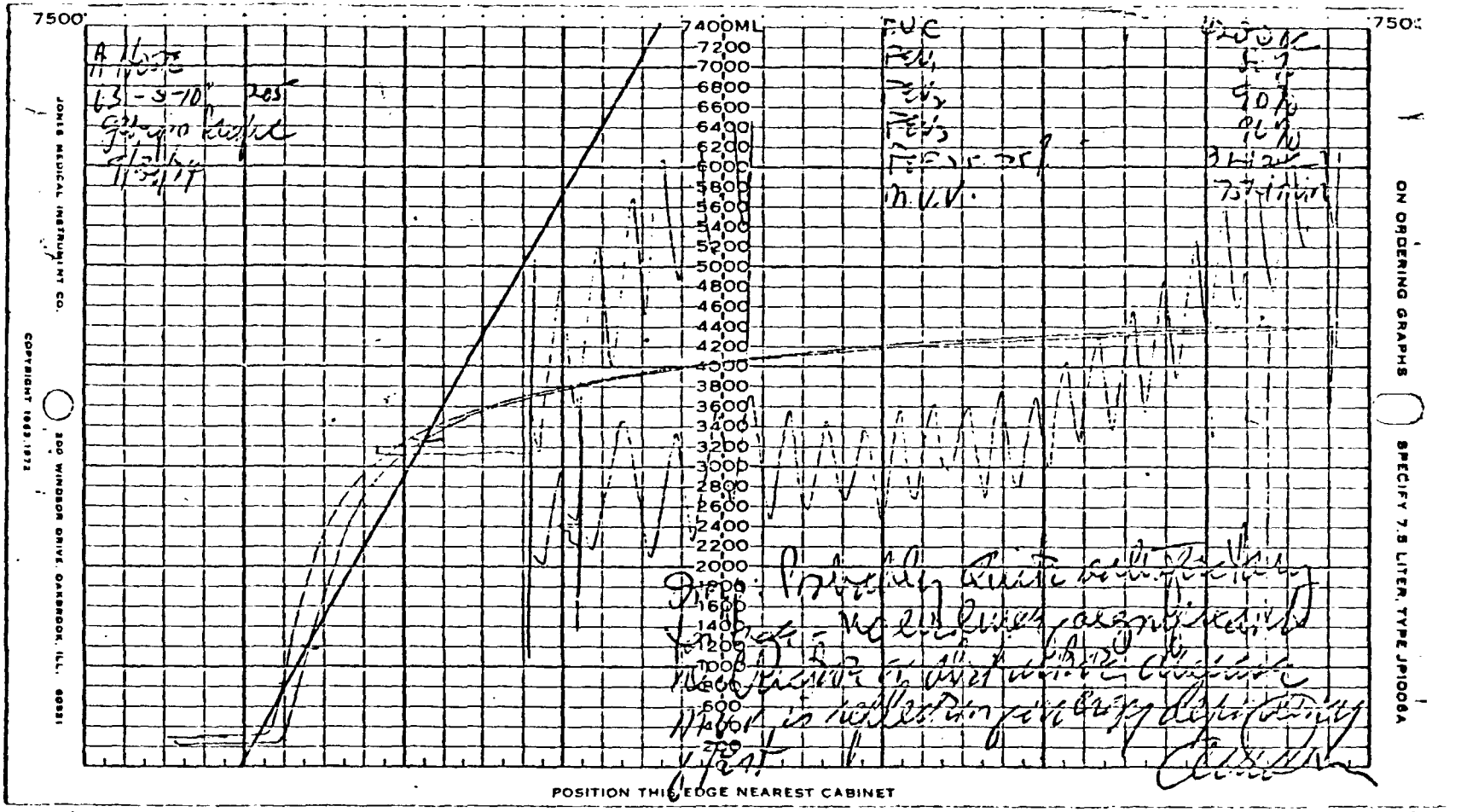
7500
7400ML
7200
7000
6800
6600
6400
6200
6000
5800
5600
5400
5200
5000
4800
4600
4400
4200
4000
3800
3600
3400
3200
3000
2800
2600
2400
2200
2000
1800
1600
1400
1200
1000
800
600
400
200
JONES MEDICAL INSTRUMENT CO.
COPYRIGHT 1969, 1972
300 WINDSOR DRIVE, OAKBROOK, ILL. 60521
ON ORDERING GRAPHS
SPECIFY 7.5 LITER, TYPE JP1000A
POSITION THIS EDGE NEAREST CABINET

KENWARD, Robert Employed: GEORGE PACIFIC

Robert A. Kenward

912 Casey Road Brown

Twin Yards

31

INDICATE YES/NO

1. COUGH
2. CHEST PAIN ✓
3. SHORT OF BREATH ✓
4. EXPECTORATION ✓
BLOOD ✓
AMOUNT/24 HRS.
1 tsp.
1 tbsp.
1 cup
1 cup
5. DO YOU SMOKE? ✓
cigars/ /day
pipe /month
1/2 [illegible] 20/[illegible]

no complaints.

DO YOU NOW HAVE OR HAVE YOU IF YES - [illegible]

	YES	NO
6. PNEUMONIA	✓	
7. TUBERCULOSIS		✓
8. ASTHMA		✓
9. CHRONIC BRONCHITIS		✓
10. HEART DISEASE		✓
11. HIGH BLOOD PRESSURE	✓	

OCCUPATIONAL HISTORY: [illegible]

WORK 1 year on packer stacker joint system

RECEIVED OCT 14 1974 Bestwall Gypsum Co. Akron, N.Y.

VENTILATION STUDY

FVC: 5000cc
FEV1: 82%
FEV2: 92%
FEV3: 100%
FEF 25%-75%: 4 L/sec
M.V.V. 120 L/min

Quite satisfactory. No evidence of either restrictive or airway obstructive disease.

SGP 0022111

[illegible] OF CHEST FILM NUMBER: 3892 #3892

The root areas are normal. There is a mild increase in bronchovascular markings into the right lower lobe but no evidence of any specific parenchymatous disease. There are no pleural findings. Trachea is in the midline. Diaphragms are smooth and all sulci are clear.

Heart shadow and bony cage are normal.

COMMENT: Status appears to be quite good. Chest x-ray is quite satisfactory. Ventilation studies are entirely normal.

[illegible]

DATE 10-2-74

MLA/kl

Marvin L. Amdur, M. D.

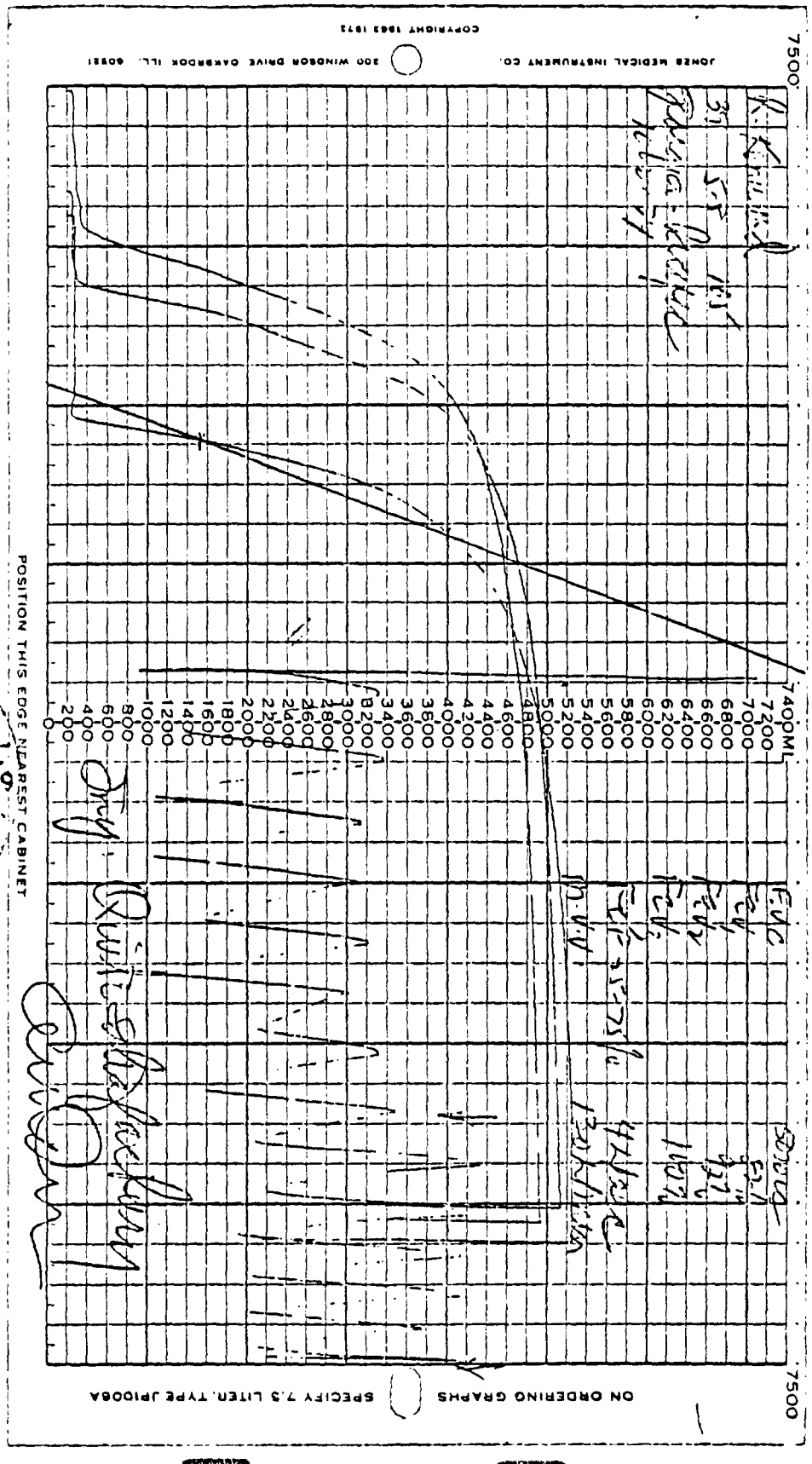

RECEIVED
OCT 14 1974
Bestwall Gypsum Co
Akron, N. Y.

Patrick Krantz

[illegible]: 11 Washington St
Akron New York 14001

[illegible]: 20 [illegible] 129-44-2601

[illegible]: INDICATE [illegible]

1. [illegible]
2. CHEST PAIN ✓
3. SHORT OF BREATH ✓
4. EXPECTORATION ✓
[illegible] ✓
AMOUNT/24 HRS.
1 tsp.
1 tbsp.
1 cup
1 cup
5. DO YOU SMOKE? ✓ [illegible]
cigars/ /day
pipe /month
cigarettes ✓
[illegible]

No significant complaint

[illegible]

[illegible]		
6. [illegible]		✓
7. TUBERCULOSIS		✓
8. [illegible]		✓
9. [illegible]		✓
10. HEART DISEASE		✓
11. [illegible]		✓

[illegible]: I work a Laborer in the mines for 1½ yrs.

VENTILATION STUDY

FVC:	4800 cc
FEV1:	84%
FEV2:	96%
FEV3:	100%
[illegible]:	41 Hrs
[illegible]:	120 L/min

[illegible]

Ventilation studies are quite satisfactory.

[illegible]: 3973

There are a few small calcific densities in the right root and in both lower lobes. Peripheral lung fields are otherwise entirely normal. Trachea in the midline. Diaphragms are smooth and sulci are clear. Heart shadow and bony cage are normal.

SGP 0022113

Impression: Satisfactory chest.

[illegible]: Ventilation studies and chest x-ray are both quite satisfactory.

[illegible]

[illegible]: 10/7/74

[illegible]

JONES MEDICAL INSTRUMENT CO.
200 WINDSOR DRIVE OAKBROOK ILL. 60521
COPYRIGHT 1983 JMI
7500
7400ML
7200
7000
6800
6600
6400
6200
6000
5800
5600
5400
5200
5000
4800
4600
4400
4200
4000
3800
3600
3400
3200
3000
2800
2600
2400
2200
2000
1800
1600
1400
1200
1000
800
600
400
200
0
POSITION THIS EDGE NEAREST CABINET
ON ORDERING GRAPHS SPECIFY 7.5 LITER, TYPE JPI006A
7500

SGP 0022114

WILLIAM NALBONE 117-34-0922
619-20TH STREET 29 X
NIAGARA FALLS, N.Y. 14301

[illegible]
1. COUGH ✓
2. CHEST PAIN ✓
3. SHORT OF BREATH ✓
4. EXPECTORATION ✓
BLOOD ✓
AMOUNT/24 HRS.
1 tsp.
1 tbsp.
1 cup.
1 cup
5. DO YOU SMOKE? ✓
cigars/ /day
pipe /month
cigarettes
1 pkg/day 7 /yrs.

no complaints

[illegible]
6. PNEUMONIA ✓
7. TUBERCULOSIS ✓
8. ASTHMA ✓
9. CHRONIC BRONCHITIS ✓
10. HEART DISEASE ✓
11. HIGH BLOOD PRESSURE ✓

[illegible]
QUALITY CONTROL SUPERVISOR IN JOINT SYSTEM DEPT. 6 YEARS

VENTILATION STUDY

FVC: 3600 cc
FEV1: 85%
FEV2: 100%
FEV3: 100%
FEF 25%-75%: 4L/sec
M.V.V. 130L/min

[illegible]

Quite satisfactory.

[illegible] OF CHEST FILM NUMBER: 4007

Mild prominence of the right root markings, increased in the right lower lobe. Peripheral lung fields otherwise not remarkable. Heart shadow, bony cage are normal.

Impression: Chest x-ray satisfactory.

SGP 0022115

[illegible]: No complaints, ventilation studies satisfactory; chest x-ray satisfactory.

[illegible]

DATE: 10/8/74

[signature]

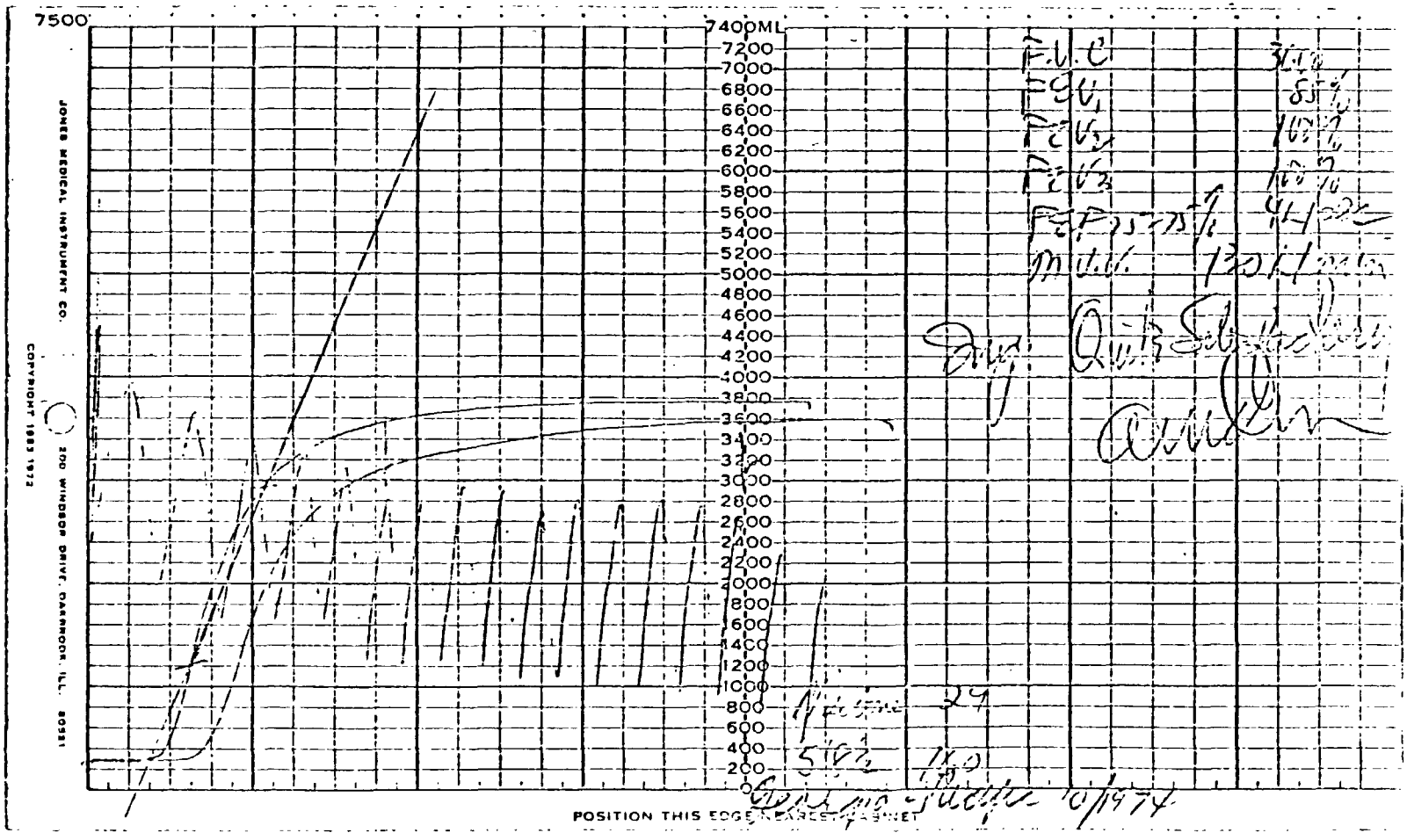
7500
7400ML
7200
7000
6800
6600
6400
6200
6000
5800
5600
5400
5200
5000
4800
4600
4400
4200
4000
3800
3600
3400
3200
3000
2800
2600
2400
2200
2000
1800
1600
1400
1200
1000
800
600
400
200
0
JONES MEDICAL INSTRUMENT CO.
200 WINDSOR DRIVE, OAKBROOK, ILL. 60521
COPYRIGHT 1968, 1972
POSITION THIS EDGE TOWARD PATIENT

REUTER, Paul Employed: GEORGIA PACIFIC

PAUL REUTER 078-42-0537

10825 STAGE RD 24 ✓

CLARENCE, N.Y. 14031

1. [illegible]		
2. [illegible]		✓
3. SHORT OF BREATH		✓
4. [illegible]		✓
[illegible]		✓
[illegible]		
[illegible]		
[illegible]		
[illegible]	✓	
[illegible]		
[illegible]		
[illegible]	1½	.7

No complaint

[illegible]		
[illegible]		✓
[illegible]		✓
[illegible]		✓
[illegible]		✓
[illegible]		✓
[illegible]		✓

[illegible]

JT. SYSTEM

[illegible] STUDY

FVC: 4800 cc
FEV1: 85%
FEV2: 95%
FEV3: 100%
FEF 25%-75%: 4.5L/sec
[illegible] 150L/min

Excellent ventilatory function. No defects.

RECEI
OCT 14 1974
Bestwall Gypsum Co.

[illegible] OF CHEST FILM [illegible]: 3897 #3897

The root areas and peripheral lung fields are entirely normal. Trachea is in the midline. Diaphragms are smooth and all sulci are clear.

Heart shadow and bony cage are normal.

SGP 0022117

[illegible]: Health status seems excellent. Chest x-ray is satisfactory and Ventilation studies could not be better.

[illegible]: 10-2-74

MLA/kl

Marvin L. Amdur, M. D.

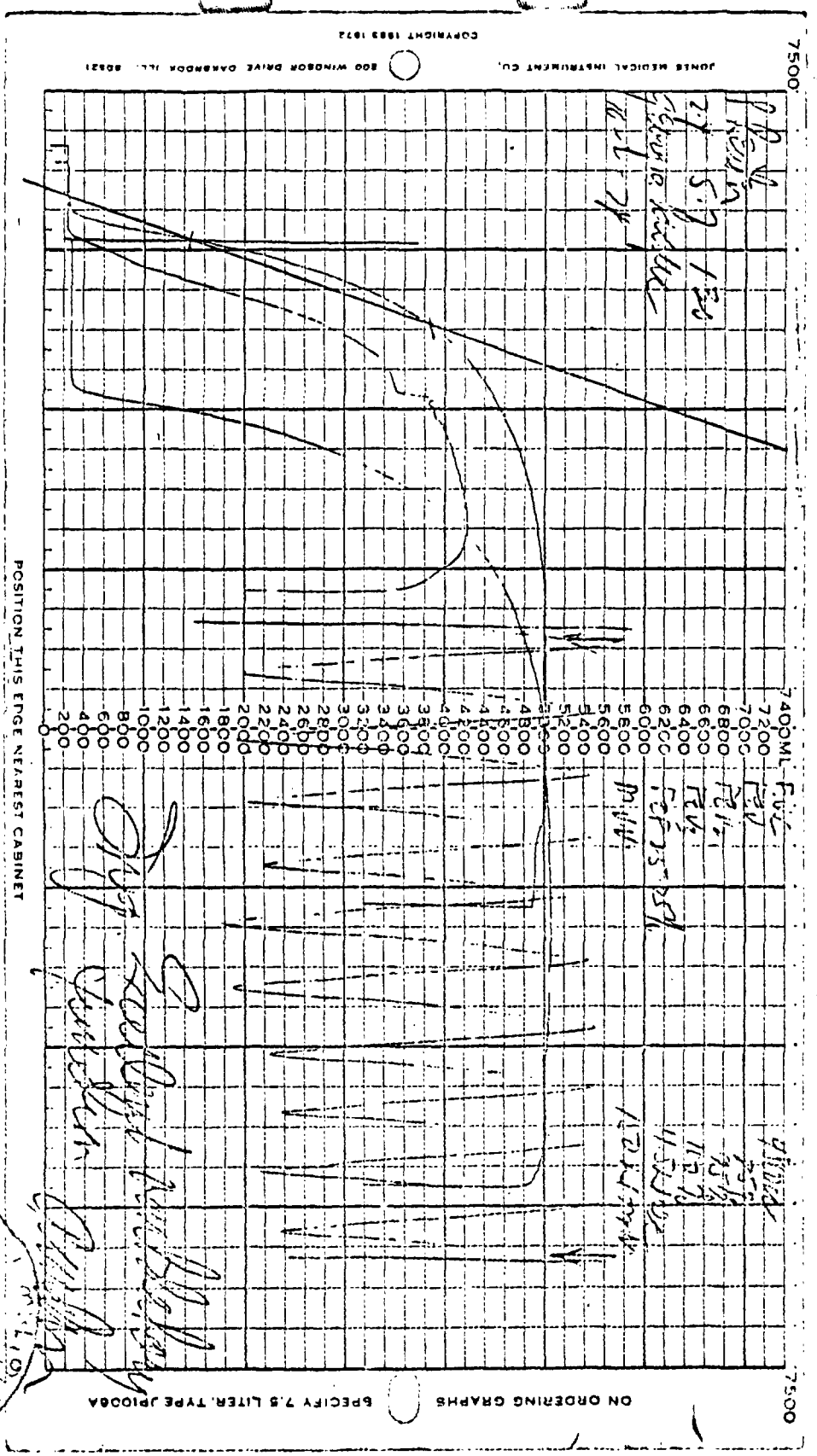

RECEIVED
OCT 14 1974
Bestwall Gypsum Co.
Akron, N. Y.

SCHEPPERLY, James L. Employed: Georgia-Pacific

James L. Schepperly 132-46-0029

29 Lewis Rd 21 ✓

Akron, New York 14001

[illegible]: INDICATE [illegible]

1. COUGH
2. CHEST PAIN ✓
3. SHORT OF BREATH ✓
4. EXPECTORATION ✓
BLOOD ✓
AMOUNT/24 HRS.
1 tsp.
1 tbsp.
1 cup
1 cup
5. DO YOU SMOKE? No
cigars/ /day
pipe /month
cigarettes
pks/day /yrs.
[illegible]

No complaint.

DO YOU [illegible] HAVE OR HAVE YOU [illegible]

	YES	NO
6. [illegible]		✓
7. TUBERCULOSIS		✓
8. [illegible]	✓	✓
9. CHRONIC BRONCHITIS		✓
10. HEART DISEASE		✓
11. HIGH BLOOD PRESSURE		✓

Asthma when younger

[illegible]: [illegible]

Lab Tester — 3 years

VENTILATION STUDY

FVC:	5400cc
FEV1:	88%
FEV2:	96%
FEV3:	100%
FEF [illegible]:	7 H/sec
[illegible]	140L/min

[illegible]

Excellent function. No defect.

[illegible]: 3844 #3844

Root areas and peripheral lung fields are entirely normal. Trachea is in the midline. Diaphragms are smooth and sulci are clear. Heart shadow, bony cage are normal.

SGP 0022119

Normal chest x-ray. Normal ventilation studies.

[illegible]: Health status would appear to be excellent.

[illegible]

[illegible]: 9/30/74

MLA/kl

Marvin L. Amdur, M. D.

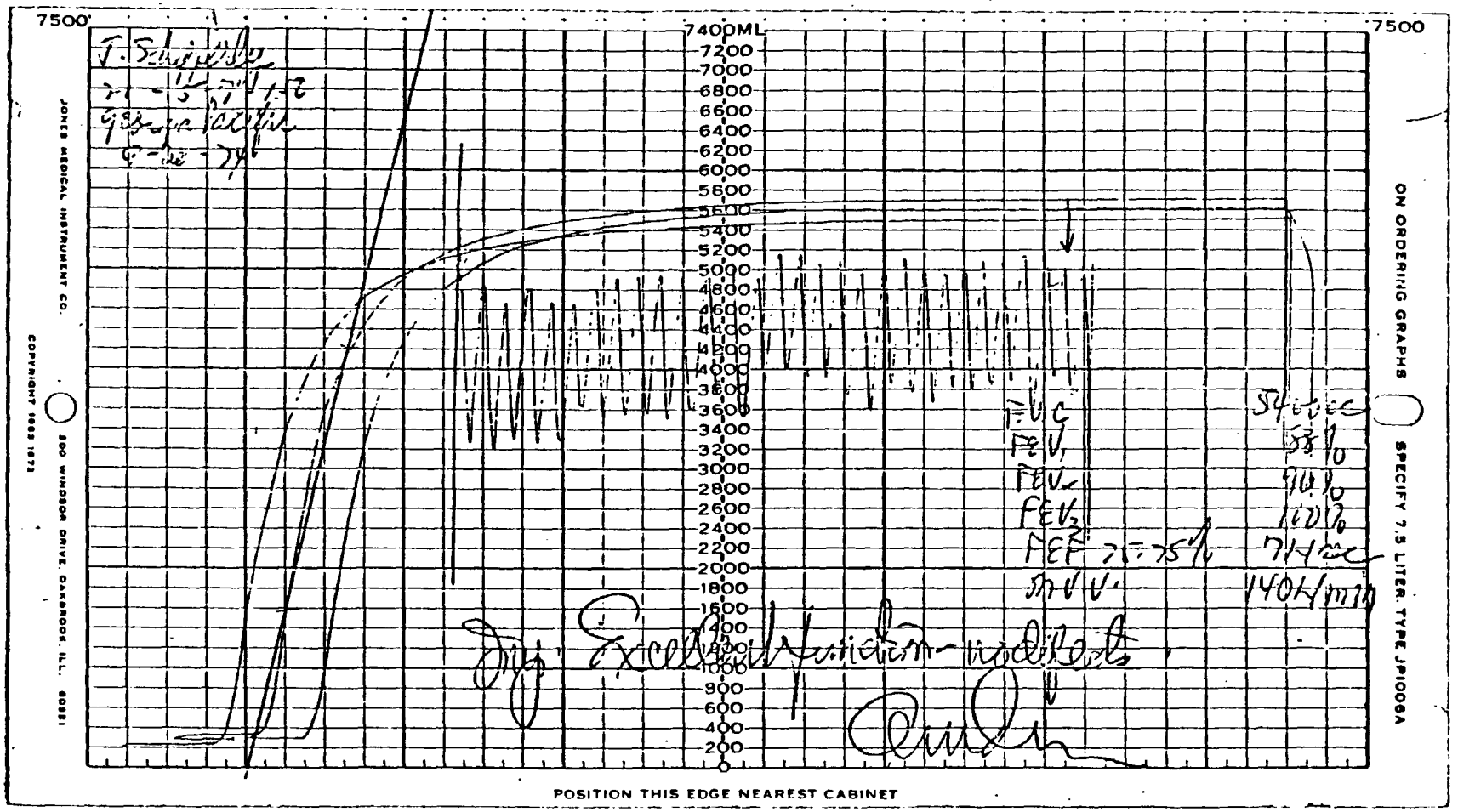
7500
7500
740 ML
7200
7000
6800
6600
6400
6200
6000
5800
5600
5400
5200
5000
4800
4600
4400
4200
4000
3800
3600
3400
3200
3000
2800
2600
2400
2200
2000
1800
1600
1400
1200
1000
800
600
400
200
0
JONES MEDICAL INSTRUMENT CO.
800 WINDSOR DRIVE, OAKBROOK, ILL. 60521
COPYRIGHT 1969, 1972
ON ORDERING GRAPHS SPECIFY 7.5 LITER. TYPE JP1008A
POSITION THIS EDGE NEAREST CABINET

Employed Georgia Pacific

[illegible] Robert G. Schiffele [illegible] 086-26-2264

[illegible]: 175 Cleveland Dr. [illegible]: 42 X

Kenmore N.Y.

[illegible]: INDICATE [illegible]

1. COUGH		X
2. CHEST PAIN		X
3. SHORT OF BREATH		X
4. EXPECTORATION		X
BLOODY		

AMOUNT/24 HRS.
1 tsp.
1 tbsp.
1 cup
1 cup

5. DO YOU SMOKE? yes
cigars/3/day
pipe 175/month
cigarettes
[illegible]/day [illegible]
[illegible]

no complaints

[illegible]

6. PNEUMONIA		X
7. TUBERCULOSIS		X
8. ASTHMA		X
9. CHRONIC BRONCHITIS		X
10. HEART DISEASE		X
11. HIGH BLOOD PRESSURE		X

OCCUPATIONAL HISTORY: [illegible]

Have worked in Gt Syst Dept off and on as supervisor

VENTILATION STUDY

FVC: 4400cc
FEV1: 86%
FEV2: 95%
FEV3: 100%
FEF 25%-75%: 5L/sec
M.V.V. 120L/min

[illegible]

Ventilation studies quite satisfactory.

SGP 0022121

[illegible] OF CHEST FILM NUMBER: 4002

Mild prominence of the root areas, minimal increase in bronchovascular markings in both lower lobes. Multiple calcific densities in each root and in the right lower lobe. Heart shadow normal in size, position and configuration. The bony cage is normal. Impression satisfactory chest.

[illegible]: No subjective complaints. Ventilation studies satisfactory. Chest x-ray satisfactory.

[illegible]

[illegible]: 10-8-74

Shawn Klemkin

JONES MEDICAL INSTRUMENT CO.
7500
7400ML
POSITION THIS EDGE NEAREST CABINET

SGP 0022122

Employed Georgia Pacific

NAME Kenneth Snyder SOC. [illegible]

[illegible]: AGE: 45

REQUIRE: INDICATE YES/NO

1. COUGH
2. CHEST PAIN — NO
3. SHORT OF BREATH — NO
4. EXPECTORATION — NO
   BLOODY — NO
   AMOUNT/24 HRS.
   1 tsp.
   1 tbsp.
   1 cup
   1 cup
5. DO YOU SMOKE? yes
   cigars* /day
   pipe L /month
   cigarettes 1-2 pack
   pks/day /yrs.
   IF NO - HOW LONG 35 yrs

no complaints

DO YOU NOW HAVE OR HAVE YOU EVER HAD? — IF YES - DESCRIBE

	YES	NO
6. PNEUMONIA		NO
7. TUBERCULOSIS		NO
8. ASTHMA		NO
9. CHRONIC BRONCHITIS		NO
10. HEART DISEASE		NO
11. HIGH BLOOD PRESSURE		

OCCUPATIONAL HISTORY: WHAT DO YOU DO AND HOW LONG HAVE YOU WORK

Load - unload 10 yrs JT. SYST. DEPT

VENTILATION STUDY

FVC: 4400 cc
FEV_1: 80%
FEV_2: 90%
FEV_3: 95%
FEF 25%-75%: 35 L/sec
M.V.V. 190 L/min

INTERPRETATION

Ventilation studies quite satisfactory.

XRAY OF CHEST FILM NUMBER: 3972

SGP 0022123

Moderate fibrosis of both roots, slight fibrosis of all lobes except for the left upper lobe where there is moderate radiolucency. This is associated with some minimal downward displacement of the left hilar area probably as a consequence of some emphysematous changes in the left upper. There are no significant evidences of pleural disease. Heart shadow though full is not abnormally so. Bony cage is normal. Impression minimal emphysema left upper lobe. Despite the absence of complaint and minimal

COMMENT: x-ray changes ventilation studies are normal. General health status would seem to be satisfactory.

BUFFALO INDUSTRIAL MEDICAL CENTER

DATE: 10/7/74

Nancy L. [illegible] M.D.

SGP 0022124

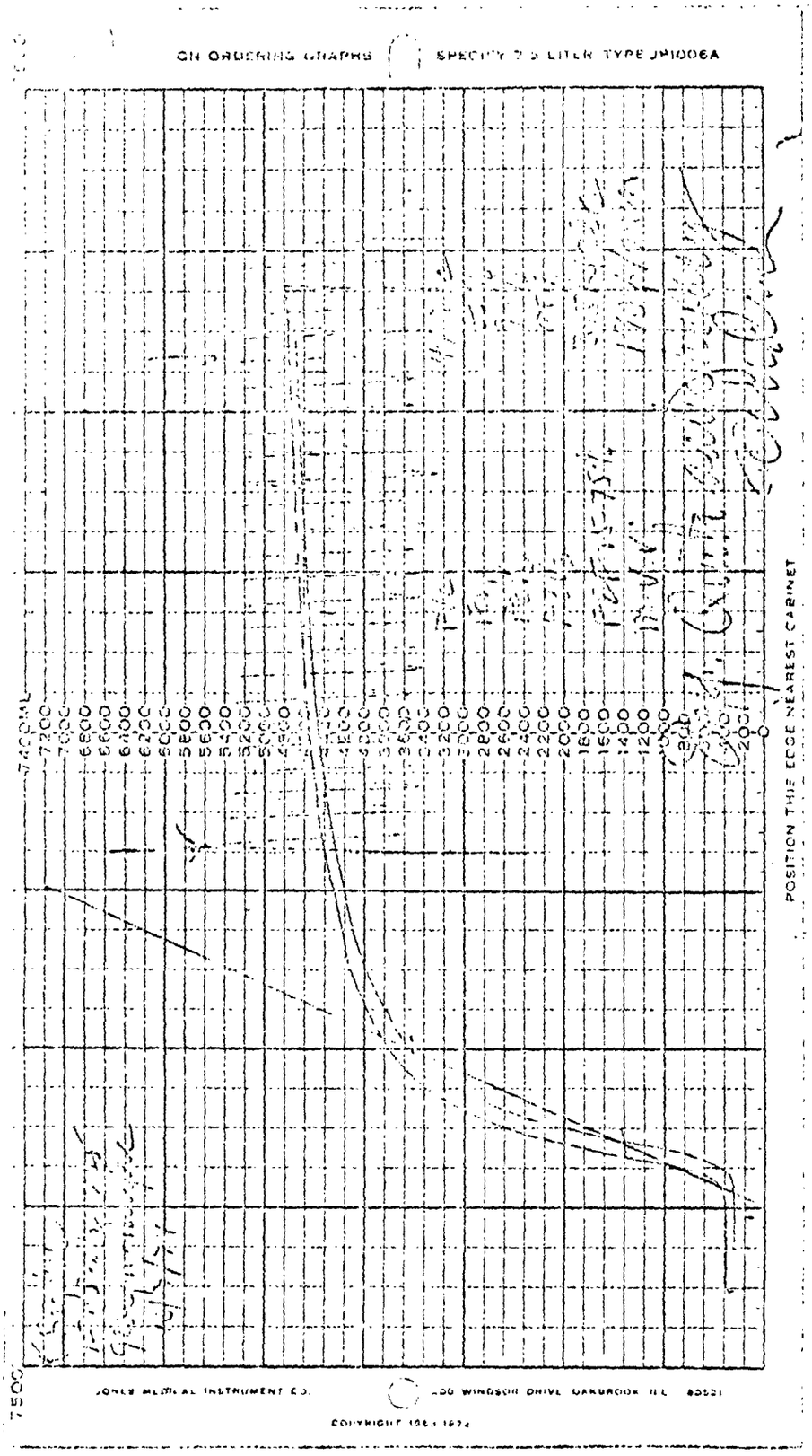
ON ORDERING GRAPHS
SPECIFY 7.5 LITER TYPE JP1006A
POSITION THIS EDGE NEAREST CABINET
JONES MEDICAL INSTRUMENT CO.
WINDSOR DRIVE OAKBROOK ILL.
COPYRIGHT

WEIBEL, Irvin Employed: GEORGIA PACIFIC

[illegible]: Irvin F. Weibel [illegible] 099-28 9757
[illegible]: 4406 S. Newstead Rd [illegible]: 36 X
Akron, New York 14001

INQUIRY: INDICATE YES/NO

1. COUGH		
2. CHEST PAIN	X	
3. SHORT OF BREATH		X
4. EXPECTORATION	X	
BLOODY		X

AMOUNT/24 HRS.
1 tsp.
1 tbsp.
1 cup
1 cup

5. DO YOU SMOKE? yes.
cigars/ /day
pipe /month
cigarettes
1½-2 [illegible]/day /yrs.
IF NO - [illegible]

no spec. complaint

DO YOU NOW HAVE OR HAVE YOU EVER HAD? IF YES - [illegible]

	YES	NO	
6. PNEUMONIA	X		- PNEUMONIA AT 7 YRS OLD
7. TUBERCULOSIS		X	
8. ASTHMA		X	
9. CHRONIC BRONCHITIS		X	
10. HEART DISEASE		X	
11. HIGH BLOOD PRESSURE	X		- ON MEDICATION AT PRESENT.

OCCUPATIONAL HISTORY: WHAT DO YOU DO AND HOW LONG HAVE YOU WORK

Joint System Dept. Supervisor - 9 years.

VENTILATION STUDY

FVC: 4800 cc
FEV1: 80%
FEV2: 95%
FEV3: 100%
FEF 25%-75%: 3.5 L/sec
M.V.V. 110 L/min.

[illegible]

Studies are quite satisfactory. There is no evidence of either restrictive or airway obstructive disease.

[illegible]: 3896 #3896

The root areas and peripheral lung fields are generally not remarkable. There is no evidence of any parenchymal disease. Trachea is in the midline. Diaphragms are smooth. Sulci are clear. Heart shadow and bony cage are normal.

SGP 0022125

RECEIVED
OCT 14 1974
Bestwall Gypsum Co.
Akron, N.Y.

COMMENT: General status would seem to be good. Chest x-ray is satisfactory. Ventilation studies are normal.

BUFFALO INDUSTRIAL MEDICAL CENTER

DATE: 10-2-74

MLA/kl

Marvin L. Amdur, M.D.

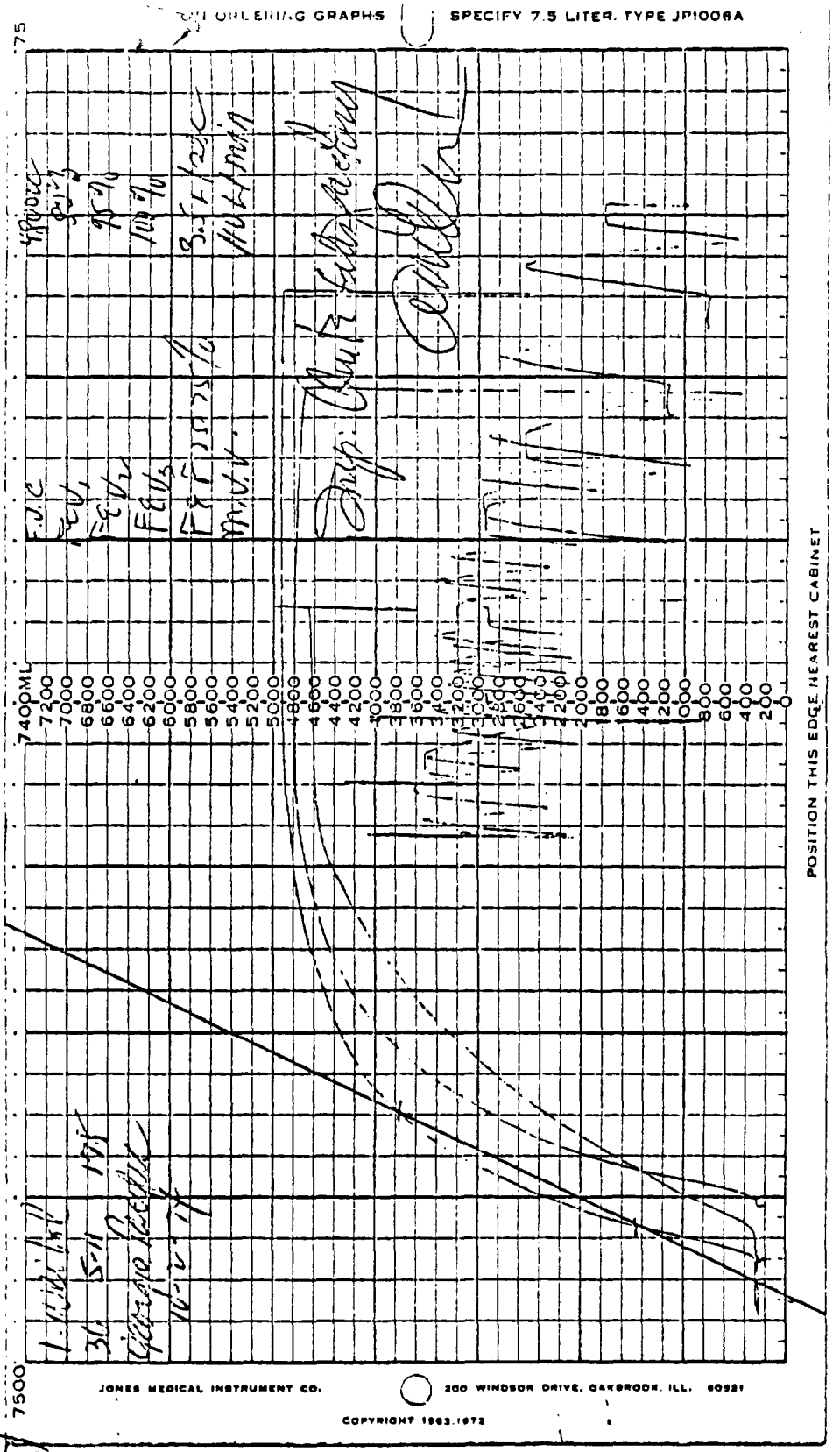

RECEIVED
OCT 14 1974
Bestwall Gypsum Co.
Akron, N. Y.