PLAINTIFF'S EXHIBIT SA-220



some needle-like crystals; the fibrocytes are few and the tissue stains poorly. The atheromatous area in the deeper portion of the intima abuts on compressed media, which also shows some hyaline and degenerative appearances, with globules of fat and infiltration with small round cells (chiefly lymphocytes). Some small vascular channels contain laked erythrocytes. The adventitia contains many dilated capillaries.

Spontaneous rupture of the pulmonary artery is a very rare occurrence and in some 10,000 autopsies only one example has been encountered by the writer. The subject was reviewed by McNaught and Dock in 1935, and in 1960 Brettell and Herrmann reported two more cases. In most of the ten cases previously reviewed the rupture was associated with congenital heart disease, especially patent ductus, and rheumatic heart disease with mitral stenosis. Neither of the two additional examples cited by Brettell and Herrmann in 1960 presented these features, but in both cases the patients were white women aged 60 years and 63 years respectively, extensive pulmonary thrombi were present and the rupture was brought on in each instance by prolonged coughing. Among the previous examples is one which was reported in 1908 by Durno and Brown—that of a man, aged 33 years, who died in his sleep. The circumstances were similar in the present case.

### References


BRETTELL, H., and HERRMANN, R. (1960), "Spontaneous Rupture of the Pulmonary Artery in Pulmonary Hypertension", *Amer. Heart J.*, 59: 263.

DURNO, L., and BROWN, W. L. (1908), "A Case of Dissecting Aneurysm of the Pulmonary Artery; Patent Ductus Arteriosus; Rupture into the Pericardium", *Lancet*, 1: 1693.

MCNAUGHT, J. B., and DOCK, W. (1935), "Spontaneous Rupture of the Pulmonary Artery", *Amer. J. Path.*, 11: 989.


## MALIGNANT PLEURAL MESOTHELIOMA IN AN ASBESTOS WORKER


J. C. McNULTY, M.B., B.Ch., B.A.O.

*Chest Physician, Kalgoorlie District Hospital, Kalgoorlie, Western Australia*


BLUE ASBESTOS has been mined in Western Australia since about 1946, and with increased production over the last 10 years, dust control and suppression have been serious problems. The asbestos vein lies in a rock body which is mainly quartzite. A number of men have developed asbestosis, silicosis and a mixed type of pneumoconiosis containing elements of both.

The blue asbestos fibre is crocidolite, and Wagner *et alii* (1960, 1961) suggested the probable relationship between exposure to this fibrous mineral and the occurrence of diffuse pleural mesothelioma. The pathological evidence for the association of these tumours with asbestos exposure was not conclusive; in only eight of 33 cases was evidence of asbestosis present. However, with one exception, there was circumstantial evidence of at least transitory asbestos exposure. In their series the mesothelioma occurred 20 to 40 years after the exposure to dust. Most authors stress the long interval between exposure to asbestos dust and the development of asbestosis, and theories of the pathogenesis of the disease have been based on this long interval and its effect on the asbestos body (Heard and Williams, 1961).

The following is believed to be the first case of pleural mesothelioma reported in an asbestos worker outside South Africa.

### Clinical Record

A white male worker, born in 1913, now employed as a labourer, had been a surface gold miner from 1937 to 1946 and a mill worker in an asbestos mine from 1948 to 1950. He had also been an occasional prospector for gold. On December 13, 1959, he was referred to the chest clinic for radiological examination of the chest. The X-ray film showed what appeared to be a small left-sided pleural effusion, but the patient refused to attend the hospital for a report or a clinical examination, and returned to the "bush".

On October 25, 1960, he was referred again to the chest clinic for examination. He had had some loss of weight, malaise, cough, moderate dyspnœa on exertion and heavy night sweats. He looked ill and wasted, and had early finger clubbing, diminished air entry to the lungs and a dull percussion note over the left side of the chest. There were a few crepitations at the base of the left lung, but none of the classical showers of fine metallic crepitations associated with asbestosis. An X-ray film of the chest showed extensive pleural thickening throughout the left hemithorax and a left lateral view showed a well-defined shadow projecting inwards from the anterior chest wall. The heart was displaced slightly towards the right. The right lung was normal. The hæmoglobin value was 12·3 grammes per 100 ml., the red and white cells were normal and the erythrocyte sedimentation rate was 125 mm. in one hour. The sputum contained asbestos bodies. An attempted aspiration of fluid from the left side of the chest was unsuccessful and a pleural biopsy, performed by Mr. F. J. Clark, produced a thickened, white, rubbery specimen, which was reported to be a malignant pleural mesothelioma.

Treatment with thiotepa was commenced and continued until the patient died in June, 1961.

### Autopsy Findings

The only relevant autopsy findings were in the left hemithorax and there was no obvious primary or secondary tumour in the right lung or the abdomen. The left lung was grossly compressed and completely enveloped in the thickened, rubbery, adherent pleura.

The pathologist (Dr. J. Stirrat) reported as follows.

> The specimen consists of two wedges of material 11 × 4 × 3 and 7 × 6 × 4 cms. The larger portion of tissue consists of a portion of spongy grey-brown lung tissue covered by the thick firm pleura measuring 1·5 cms. in thickness [Figure I]. The smaller portion

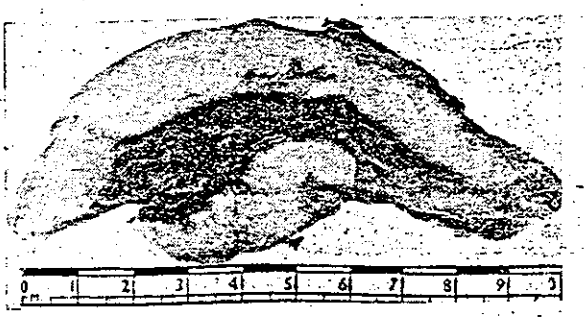


FIGURE I

> of tissue is spongy grey-brown lung with a smooth pleural surface in which there is one small grey-black nodule. Microscopic: Sections show a poorly differentiated malignant tumour infiltrating the pleura and adjacent lung tissue. This tumour consists of pleomorphic cells which tend to line spaces and form small knots and pseudotubular structures: in some instances the space lining cells are flattened or low cuboidal in type, mitoses are present, but are not numerous. There is a marked fibrous tissue stromal increase in the pleura [Figure II].[1]
>
> In addition to the tumour, there is a nodular hyaline fibrosis in the lung showing the whorling around light brown crystaline deposits, characteristic of silicosis [Figure III] together with a more diffuse interstitial fibrosis of the lung with asbestos bodies in considerable numbers distributed in this fibrous stroma [Figure IV]. Lastly there is an acute bronchopneumonia present.
>
> The malignant lesion is a pleural mesothelioma as previously diagnosed by pleural biopsy. This is superimposed on a lung showing the combined picture of

[1] For Figures II to IV see art-paper supplement.

silicosis, asbestosis and a terminal bronchopneumonia. Diagnosis: Pleura — pleural mesothelioma; Lung — asbestosis and *silicosis* — *bronchopneumonia*.

### Discussion

There appears to be a relationship between exposure to blue asbestos and the development of the pleural mesothelioma in this case. Pleural mesotheliomas are very rare tumours and details are known of only three cases in Western Australia. Asbestosis has, regrettably, become less rare, but there are less than 40 known cases in the State. The relatively short period of exposure to blue asbestos dust confirms an impression received from Wagner *et alii* (1960, 1961) that these tumours may arise after transitory exposure to crocidolite in susceptible persons.

Experience in Western Australia certainly confirms that blue asbestos is a very harmful and lethal fibre. The dust is one that urgently requires further experimental study (Barnes, 1961). The interval between exposure and the development of the tumour is much shorter than has been previously reported. This also applies to the interval between exposure to blue asbestos and the development of asbestosis in this State, which in one instance was less than four years.

The surface gold mining in which the patient was engaged may have contributed to the silicosis which was present, but silicosis is rarely found in Western Australian gold miners with only 10 years' surface mining experience.

### Summary

A case is reported of malignant pleural mesothelioma in an asbestos worker suffering from asbestosis and silicosis after two years' work in a blue asbestos mill 10 years previously.

### Acknowledgements

My thanks are due to Dr. S. Webster, for referring the patient; to Dr. W. Harris and Dr. D. D. Letham, for helpful advice; and to the Public Health Commissioner, Dr. L. Henzell, for permission to publish this case.

### References

BARNES, J. M. (1961), "Mode of Action of Some Toxic Substance", *Brit. med. J.*, 2: 1079.

HEARD, B., and WILLIAMS, R. (1961), "The Pathology of Asbestosis with Reference to Lung Function", *Thorax*, 16: 264.

WAGNER, J. C., SLEGGET, C. A., and MARCHAND, P. (1960), "Diffuse Pleural Mesothelioma and Asbestos Exposure in the North Western Cape Province", *Brit. J. indust. Med.*, 17: 260.

WAGNER, J. C., SLEGGET, C. A., and MARCHAND, P. (1961), "Diffuse Pleural Mesothelioma in South Africa", *S.A. med. J.*, 35: 28.

---

The problem of the chronic patient can be summed up as that of a patient who wants to be dependent, and a doctor who cannot allow independence because he himself is too anxious. In order that the doctor be able to help at all, the patient must at some time, in some way, and to a varying extent, be in a dependent position; but the occasion, mode, and degree of dependence must be as nicely judged as the dose of a toxic drug. Recovery is the regaining of independence—a growing up and maturation. The organization of hospitals too readily enables the patient to become dependent by insisting upon too great a degree of dependence; any show of independence is frowned upon. Drug therapies, especially, facilitate dependence and regression to the position of a passively fed child. Not enough attention is paid to the psychological implications of illness and its treatment, whether the illness be primarily physical or not.

Nobody can mature without discomfort—even pain—or without experiment and risk. *Too much modern therapy* deprives the patient of these essentials to growth, instead of helping him to use them to his advantage. The parent cannot hope to see his child grow up emotionally if the child is not allowed freedom even though this be potentially dangerous. He must guide without restricting, and even, on occasion, not respond to the child's pleas for help, insisting that he cope with the situation himself. To do things for others is to deprive them of the opportunity of doing them for themselves—perhaps for ever.—G. A. Heasman, "The Patient, the Doctor, and the Hospital", *Lancet*, 1962, 2: 59 (July 14).

## MENDELSON'S SYNDROME IN OBSTETRICS

I. K. FUBLER, M.R.C.O.G.
*Medical Superintendent*
AND
J. DAVENPORT, M.R.C.P.E., F.F.A.R.A.C.S.
*Anæsthetic Registrar*
*The Queen Victoria Maternity Hospital, Rose Park Adelaide*

MATERNAL HAZARDS arising from pregnancy have been greatly reduced in the last 20 years, with the increased efficiency of blood replacement, the advent of antibiotics and improved antenatal care, particularly with regard to pre-eclamptic toxæmia. Maternal mortality reports stress three conditions—the classical triad of eclamptic toxæmia, hæmorrhage and sepsis—as being the main causative factors, but we believe that obstetric anæsthesia is still under-estimated as a cause of maternal mortality. There were 12 maternal deaths amongst 25,072 public patients at the Queen Victoria Maternity Hospital, Adelaide, in the period from 1952 to 1961. Four of these deaths were due to the aspiration into the lungs of liquid stomach contents (Mendelson's syndrome); thus this syndrome was the most important single cause of maternal death.

In the Report by the Special Medical Committee Investigating Maternal Mortality in New South Wales (1960), nine deaths were stated to be associated with anæsthesia, and of these, seven were ascribed directly to the anæsthetic. Very litle detail is given, but one death is stated to be due to the inhalation of vomitus, and it is possible that, in Cases 38 and 39 in the section on cæsarean section, death was also due to Mendelson's syndrome. In some cases in other maternal mortality reports, in which death is stated to have been due to "obstetric shock" and amniotic fluid embolism, death was, in our opinion, possibly due to this syndrome, and this will be the subject of a later report. As Wrigley (1947) points out, the situation still exists, even in teaching hospitals, in which inexperienced members of the staff are called upon to administer potentially dangerous anæsthetics to patients in labour. Another aspect which drew comment in the New South Wales report is that the general anæsthetic administered in some of these cases *is tragically* unnecessary.

The following case is described as it demonstrates most of the characteristics of Mendelson's syndrome.

### Clinical Record

A woman, aged 26 years, was admitted to the Queen Victoria Maternity Hospital on July 27, 1961. In 1960 a surgical induction of labour for "post-maturity" of the fœtus had been carried out, and it had been followed by *the normal delivery of a baby weighing* 2·7 kg. There was no history of relevant previous illness. The present pregnancy had been quite normal, and throughout the patient's blood pressure had remained in the region of 120/70 mm. of mercury; her urine was normal, the presenting part was the vertex and the head was engaged at 39 weeks. She was admitted at 42 weeks' gestation because of "post-maturity"; at this stage the obstetric position was unchanged, and next day a synthetic oxytocin ("Syntocinon") infusion was given, after which the membranes were artificially ruptured. Labour began several hours later. *The first stage lasted three* and a half hours, but after one hour in the second stage a persistent occipito-posterior position of the head was diagnosed.

Atropine (0·6 mg.) was given intravenously and general anæsthesia was induced with nitrous oxide, oxygen and trichloroethylene ("Trilene"), in preparation for a forceps delivery. During the induction of anæsthesia the patient vomited, and, although the pharynx was aspirated immediately, it appeared that some of the fluid stomach contents were inhaled, sounds of moisture in the trachea

## ILLUSTRATION TO THE ARTICLE BY K. M. BOWDEN



FIGURE I: Low-power photomicrograph showing the three layers of the wall of the ruptured pulmonary artery. A calcified area is visible in the lower left corner. Very little remains of the elastic lamina. The main changes are present in the deep intima.

## ILLUSTRATIONS TO THE ARTICLE BY J. C. McNULTY



FIGURE II.



FIGURE III.



FIGURE IV.