#3
Aroclors

55

Reprinted from The Journal of the American Medical Association
May 15, 1943, Vol. 122, pp. 158-161
Copyright, 1943, by American Medical Association

AN OUTBREAK OF HALOWAX ACNE ("CABLE RASH") AMONG ELECTRICIANS

Aroclor

LOUIS SCHWARTZ, M.D.
Medical Director, United States Public Health Service
BETHESDA, MD.

The first observations on the development of acnelike lesions among workers in the United States coming in contact with chlornaphthalenes and chlordiphenyls as well as acute yellow atrophy of the liver occurring among such workers were reported[1] in 1935. Since that time many authors have reported similar observations.

Despite the fact that these compounds, if used without proper safety precautions, cause a high incidence of skin conditions and, in certain processes such as coating wires, also entail the serious hazard of acute yellow atrophy of the liver, they are still being used as dielectrics and insulators, because they are waterproof and have excellent heat resisting and flame proof properties.

Since our entrance into the war, the speed-up in our shipyards has in many instances resulted in failure to install the proper safety precautions necessary when handling wires insulated with these substances.

Reports have been received by the U. S. Public Health Service from several shipyards of acnelike lesions occurring among electricians installing heat and flame proof cables in ships. Investigations have always shown that the cables causing the trouble were coated with chlornaphthalenes and chlordiphenyls (halowax). The most recent investigation was made in response to a request from the health officer of one of our Western states for an investigation of an outbreak of dermatitis among electricians working in the ship-

From the Dermatoses Investigations Section, Division of Industrial Hygiene, National Institute of Health, U. S. Public Health Service.
1. Schwartz, Louis: Dermatitis from Synthetic Resins and Waxes, J. Pub. Health 25:1586 (June) 1936.

MONS 097958

yards of that state. The electricians had become alarmed because some among them had developed acne-like lesions; they had read in the newspapers of three workers who had died of acute yellow atrophy of the liver at the plant where the wires with which they worked were made. It was only with great difficulty that these electricians were persuaded to remain at their work until the arrival of the representative of the U. S. Public Health Service to make an investigation.

Immediately on his arrival, a conference was arranged to bring together representatives of the workers' unions, representatives of the state health department and superintendents of the shipyards. At the meeting it was decided to visit all shipyards where the so-called "cable rash" was reported and to examine the workers suspected of having "cable rash" in order to ascertain whether all the cases of dermatitis were caused by handling cables.

In the first shipyard visited it was found that dermatitis was limited to cable "strippers." The work was performed in the intercommunication room of the ship. In plant A, 8 persons were presented for examination as suffering with "cable rash." Seven of these were found to have halowax acne. In plant B, 22 cases, all halowax acne, were presented; all of these occurred in electricians engaged in "stripping" cable. In this shipyard, electricians affected worked for several months on "stripping" cable in the intercommunication room. They stated that about two months had elapsed before they noticed signs of the acne on the face. Those who had worked longest were most severely affected. None of the workers showed signs of systemic poisoning. Samples of the wire which the workers "stripped" were examined. It was noted that one of the cables made by the company where deaths had been reported contained considerable amounts of halowax impregnated into asbestos and wrapped around the wire as insulation. The halowax was loosely contained in the asbestos and flaked off easily as the wires were being "stripped."

In the second shipyard visited it was found that the "strippers" worked only part time at "stripping" and at other electrical work the rest of the day. It was also found that the type of cable described was not being used. There was being used, however, another

MONS 097959

type of cable made by the same company from which the halowax did not flake off so readily. Twenty-one electricians who had been engaged at various times in "stripping" were presented for examination. While various skin conditions were noted, such as insect bites, impetigo and pruritis hiemalis, there were no cases of halowax acne.

In the third shipyard visited it was again found that cable being "stripped" was not the type from which the halowax flaked easily and the electricians worked only part time at "stripping." Nineteen cases of so-called cable rash were presented for examination but none of them proved to be halowax acne. They were the various skin diseases such as those found among workers in the second shipyard inspected.

In the fourth shipyard the operation performed by the electricians was the same as observed in the other yards. Among 12 cases of so-called cable rash presented for examination there were no cases of halowax acne.

Samples of cables from all four yards were compared. It was found that the cable most used at the first shipyard and to which the workers attributed the "cable rash" was so coated with halowax that in the "stripping" operation the halowax flaked off easily and scattered on the hands and clothes of the "strippers." Moreover, at this shipyard more halowax coated cable made by the company where the deaths had been reported was used than at any of the other yards. Workers at this shipyard had been engaged in "stripping" for a longer time than in the other shipyards and "stripped" all day instead of only part of the day as in the other shipyards. Cables made by other companies were found to have halowax insulation, but the halowax was more tightly held against the wire and more firmly impregnated into the asbestos so that it did not flake easily.

From this investigation it seemed evident that the constant handling of cable in which halowax is loosely packed and flakes off is responsible for the acne occurring among the "strippers" in the first shipyard inspected.

When this conclusion was reached, a meeting with the dermatologists of the city was held and cases of halowax acne were presented. This was done with the

MONS 097960

purpose of acquainting physicians with the disease and outlining for them approved methods of treatment.

The diagnosis of halowax acne was determined by (1) the history of industrial exposure to halowax, (2) the appearance of the lesions and (3) their location. The history will show that the worker was engaged in an occupation in which he came in contact with halowax or its fumes for a period of a month or more before the lesions began to appear. In this case the occupation was "stripper" of wires on heat and flame proof cables insulated with halowax. Lesions are pinhead to pea size pale straw colored cysts formed by plugging of the orifices of the sebaceous glands, resulting in retention of the secretion and in the keratinization of the lining membrane. Cysts are located on the face, lobes of the ears, retroaural folds, back of the neck, shoulders, abdomen around the navel, thighs and wherever the halowax soiled clothes may touch the skin. It is not unusual to see similar lesions in the wife and children of the worker caused by contact with the soiled work clothes, if they are worn or washed at home.

Once seen, halowax acne (fig. 1) cannot be mistaken for anything else except perhaps coal tar pitch acne, from which it can be differentiated by the history of the occupational exposure. Acnes caused by chlordiphenyl, chlornaphthalenes and chlordiphenyloxide are identical in appearance with halowax acne. It is possible for the uninitiated to confuse acne vulgaris with halowax acne, especially if the halowax acne occurs in a patient of acne age.

The differential points other than age and occupational exposure are given in table 1.

The microscopic examination of a typical halowax cyst (fig. 2) made by Surgeon Samuel M. Peck (R) is as follows:

The epidermis shows relatively little, except for some scaling without parakeratosis. We see the evident widening of the follicular openings and the formation of hyperkeratotic plugs. Here are seen horned cysts down in the cutis and, in the deeper portions of hair follicles, both in and around it, there is a marked inflammatory reaction. An almost tuberculoid granulation tissue is seen consisting of dense accumulations of both foreign body and Langerhans type of giant cells. Between these giant cells are many histiocytes and lymphocytes, the histiocytes in many instances having the characteristics of epithelioid cells. In the serial sections it can be seen that

MONS 097961

these horned cysts situated in the middle cutis are extensions of the enlarged hyperkeratotic follicles in which the whole follicular apparatus has been replaced by a huge invaginated structure full of horny material which has pressed against the rest of the structure causing atrophy with the resultant formation of horned cysts. Also from the serial sections it is



Fig. 1.—Halowax acne on an electrician: note cysts behind ears and on ear cartilages.

evident that the dense mass of foreign body granulation tissue reaction is situated in and around remnants of sebaceous glands and hair bulbs.

Interpretation.—The process is analogous to acne in that we have plugging of the follicular openings, follicular and perifollicular inflammatory reactions and a foreign body giant reaction which is often associated in acne with the escape of

MONS 097962

sebaceous gland contents into the surrounding tissues. It *differs from* acne in that the plugging of the follicular openings is due almost exclusively to a hyperkeratotic process which seems to include not only the mouth of the hair follicles, but also extends downward, following the invagination into the associated structures. In acne we ordinarily have a combination of follicular hyperkeratosis and excessive secretion of the sebaceous glands. The last seems to play a very little role in this process. There is no real comedo present, but more like the follicular hyperkeratosis seen in ordinary vitamin A deficiencies.[2]

Of most importance in the treatment of these cases is the treatment of the skin with tincture of green soap or a synthetic wetting agent. The synthetic wetting agent is to be preferred and should consist of 10 per

TABLE 1.—*Differential Points*

Haliowax Acne	Acne Vulgaris
Usually occurs on face, behind ears, on neck, chest, abdomen	Usually occurs on face, back and chest
Comedones, while present, are not a prominent feature	Comedones are a predominant feature
Acnelike lesions are usually pale, straw colored, noninflammatory cysts	Lesions are inflammatory
Contents of cysts consist mostly of keratin plus sebaceous matter	Contents of lesions consist of sebaceous matter and inflammatory exudate
The skin may be dry.....	The skin is greasy
The lesions are persistent.....	Individual lesions are transient

cent aqueous solution of either Igepon, Duponol, Santomerse, Naccanol or Aerosol. It is not advisable to add a sulfonated fatty oil to the wetting agent because the sulfonated fatty oils decrease, if anything, the defatting powers of such a solution of wetting agent as is given.

Comedones should be expressed and cysts evacuated two or three times each week. The comedones may be expressed by the nurse in the plant, but a physician should perform all operations which require incision of the skin in order to evacuate cysts. A mild peeling solution such as lotio alba is advised for use at night. If x-rays are used, they should be administered with great caution especially if the patient is beyond the acne age,

2. Schwartz, Louis, and Barlow, Frank A.: Chloracne from Cutting Oils, Pub. Health Rep. 57: 1747-1752 (Nov. 20) 1942.

MONS 097963

as in these patients the skin is usually dry and further depression of the function of the sebaceous glands is not desirable.

At the final meeting of the representatives of the health department, the workers and superintendents of

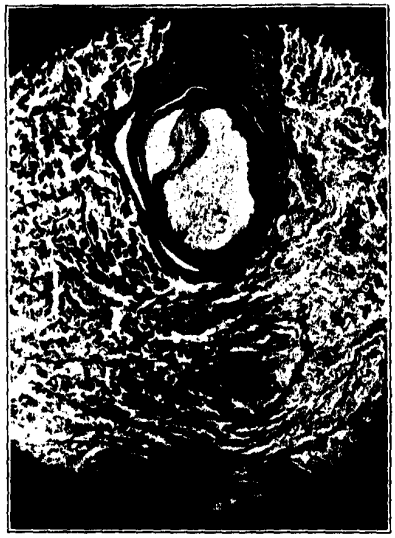

Fig. 2.—Biopsy section of chloracne from chlornaphthalenes and chlordiphenyls (reduced from photomicrograph originally published in Public Health Reports [8]).

the shipyards the following recommendations were made:

Since no cases of halowax acne were found in three of the yards, there need not be any special precautions

MONS 097964

taken by the electricians in these yards as long as they handle the same kind of cables as they have been handling and as long as they do not spend most of their time in "stripping"; however, if at any time they must handle the special cable with the loose halowax insulation, they should also take these precautions:

1. It is recommended that workers engaged in "stripping" cable containing either chlornaphthalene, chlordiphenyl or chlordiphenyloxide be supplied with hood respirators. It is preferable to have these hood respirators made from a transparent synthetic resin such as pliofilm or vinylite or perhaps a fireproof cellophane. The eye piece should be a large flat plate of lucite rather than the conventional double lenses. The respirator

TABLE 2.—*Tetryl Protective Cream*

	Per Cent
Shellac	12.90
Isopropyl alcohol	30.92
Bodied linseed oil	3.70
Stearic acid	0.92
Flexol	0.02
Carbitol	3.08
Talcum powder	20.18
Ferric oxide	0.15
Titanium dioxide	9.88
Sodium bicarbonate	3.08
Sodium perborate	14.91

should be closely fitted to the nose and contain such filters as will efficiently filter out dust and wax.

2. The "strippers" should be supplied with clean coveralls daily, the coveralls to be laundered at the shipyard.

3. "Strippers" should wear long underclothes cleaned daily at the shipyard.

4. "Strippers" should be required to take a shower bath before going home and they should be furnished with toilet soap for this purpose.

If, for any reason, the hood respirator advocated cannot be obtained or used, a substitute not quite as good will be found in protective ointments for the face, neck and ears. The ointments should be of the type that coat the skin with a dry film that prevents the halowax from touching the skin and also prevents the soiled fingers from getting in contact with the skin. It is believed

MONS 097965

that the tetryl protective cream developed by the U. S. Public Health Service would answer this purpose. The formula for this cream is given in table 2. This preparation is now being manufactured.

The tetryl protective cream consists essentially of an alcoholic solution of shellac mixed with sodium perborate and zinc oxide. When it is applied to the skin the alcohol evaporates in about ten minutes and leaves a dry adherent coating on the skin which is difficult to remove unless it is washed off with soap and water. A somewhat similar preparation consists essentially of an aqueous solution of casein and zinc oxide and is also being manufactured.

If these ointments are used they should be applied before going to work, washed off before going to lunch, reapplied after lunch, and again washed off before going home. The clean coveralls and clean underclothes should be compulsory even if the ointment and hood are used.

It is also recommended that those workers who have halowax acne be given precautionary liver function tests, not because it is thought that they have liver damage but rather in order to make certain they have not. Liver damage does not ordinarily occur in workers handling the dry chlorinated hydrocarbon waxes. It has been found usually to occur among workers handling the molten waxes or the waxes in solution. In such instances the fumes are inhaled.

Safety directors of the shipyards were advised to report to the industrial hygiene division of the state board of health any cases of acne occurring among electricians in order that investigations may be made in time to prevent further outbreaks.

Printed and Published in the United States of America

MONS 097966